Volume : 02 Number : 02 July - Dec 2016 Publication : Half Yearly

ISSN 2394 - 6822

International Journal of Ethics, Trauma & Victimology

SUPPORTED BY SPIC

Editor-in-Chief:
Dr. R.K. Gorea

Associate Editors:
Dr. A.D. Aggarwal
Dr. A. Garg

International Journal of Ethics, Trauma and Victimology being released
at A CME in the College of Medicine, Prince Sattam bin Abdulaziz University, Al Kharj,
Kingdom of Saudi Arabia by the vice dean of College of Medicine

Members of the Middle East wing of the SPIC at the time of release of Journal

INTERNATIONAL JOURNAL OF ETHICS, TRAUMA & VICTIMOLOGY

Journal supported by
Society for Prevention of Injuries and Corporal Punishment(SPIC)

AIMS AND SCOPE

This journal is published to expand the academic activities and spread the knowledge, ideas and latest research in the field of ethics, trauma, and victimology. This journal publishes original research papers, review articles, case reports, letters to the editor and review of books on ethics, trauma, and victimology. This journal is supported by Society for Prevention of Injuries and Corporal Punishment (SPIC). This journal is supporting the aims of the Society. This journal also highlights the achievements of the SPIC and its members.

This journal covers the various aspects of ethics, evidence-based medical ethics, ethical dilemmas and various dynamic issues related to ethics. It also covers the ethical issues related to Forensic Nursing Science, Forensic Odontology, and Forensic Psychiatry. It also covers the ethical aspects of Toxicology including Environmental Pollution. It covers issues related to all sorts of corporal punishment and their prevention, particularly in schools. It covers physical as well as psychological aspects of trauma and clinical forensic medicine related to all types of injuries and prevention of injuries. It covers all aspects of Victimology including etiology, crime scene investigation and prosecution.

Editor in Chief

Dr. RK Gorea
Professor Emeritus, JJT University, Rajasthan, India
&
Faculty Member & Course Coordinator, College of Medicine
Prince Sattam bin Abdulaziz University, Kingdom of Saudi Arabia

Associate Editors

Dr. AD Aggarwal
Associate Professor
Department of Forensic Medicine
Government Medical College
Patiala, 147002
India

Dr. A Garg
Associate Professor
Department of Forensic Medicine
BPS GMC forwomen
Khanpur Kalan, Gohana, Sonipat
India

Executive Editorial Board

Publication Manager: **Mr. Abhinav Gorea**, Australia
Assistant Scientific Manager: **Dr. Gulam Mustafa**, KSA
Assistant Art Manager: **Mr. Zafar Shahbaz**, India

Editorial Board

Dr. A Al Theyab
Dean, College of Medicine
Salman bin Abdulaziz University
Kingdom of Saudi Arabia

Dr.ZbigniewFedorowicz
Advisor: HRH.
The PrimeMinister'sOffice
Kingdomof Bahrain

Dr. Clifford Parera
Medico-Legal Specialist
Department of Forensic Medicine
Faculty of Medicine
University of Ruhuna
Sri Lanka

Dr.Magdy A Azim Kharoshah
Editor in chief
Journal of Forensic Science
Egypt

Dr. Kathleen A Carson
Former Policy, Research, and Training Officer
Billings Police Department
City of Billings, Montana
USA

Dr. B N Yadav
Professor and Head
Department of Forensic Medicine
BP Koirala Institute of health Sciences,Dehran,**Nepal**

Dr. Sanaa Kamal
Department of Gastroenterology
Ain Shams, Faculty of Medicine
Cairo, **Egypt**

Dr. Parul Khare Sinha
Assistant professor
Department of Oral Pathology
College of Stomatology
Ninth peoples Hospital
Shanghai Jio Tong University School of Medicine
639, Zhi Zao Ju Road, Shanghai
China

Ms. Virginia A Lynch
Founder President
International Association of Forensic Nurses
Colorado Springs, Colorado
USA

Dr.Kulanthayan K C Mani
Department of Community Health
Faculty of Medicine and Health Sciences
University Putra Malaysia
43400 Serdang, Selangor
Malaysia

Dr. Abdul Rasheed Mian
Dean
Mohtarma Benazir Bhutto Shaheed Medical College, **Mirpur**

Dr. Ahmet SadiCagdir
Ministry of Justice
Council of Forensic Medicine
Istanbul, **Turkey**

Dr. Fanny Sara Reisfeld
AnnieRey Consulting
Poder Judicial de la Nación
Argentina

Dr.AlirezaMoghisis
Former Director for Health Performance, Assessment & Quality Assurance
& Estimating Burden of Diseases.
Ministry ofHealth and Medical Education
No.35, ToghaniAv,Laleh St.
Shahran,
Tehran, **Iran**

Prince Ache Julius Ogu
Chief Executive officer atRoad Accident
PreventionNetwork Centre (RAPNEC)
Ndamela House Plot 500 Suit B1
Tafawa Balewa Way Area 3
Abuja,**Nigeria**

Dr.Shrein S Ghaleb
Head of Department of Forensic Medicine& Clinical Toxicology
BeniSueif University
Egypt

Dr. Mutaz A Alqazzaza
Head of the Dept. of Pathology and Forensic medicine
Professor and Consultant in Forensic Medicine
College of Medicine
University of Al-Nahrain
Iraq

DR. Nagi A Abdullah
Forensic medicine unite
Para clinic department
Faculty of Medicine and health Sciences
Aden University
Yemen

DR. Mahmud Kaddura
Department of Forensic Medicine & Toxicology
Faculty of medicine
Benghazi University
Libya

Dr. Hussein Chahrour
The Lebanese Ministry of Justice, Sami Solh Avenue, Parc sector, Beirut,
Lebanon.

Dr. Jagmohan Singh
50 Ice Fields Road, Brampton
Ontario, **Canada**. L6R 3G8

Dr. Akbar Pathan
Sr. Application Specialist
Integrated Gulf Biosystems
P.O. Box 250310, Riyadh- 11391
Kingdom Of Saudi Arabia

Sang-Seob Lee
Section of Forensic Dentistry
Medical Examiner's Office
National Forensic Service
Wonju, **Korea**

Issuance:
Half yearly

The first volume of the journal published in2015

Founder Editor in chief
Dr. RK Gorea
Email: editoretv@gmail.com

Founder Associate Editors
Dr. AD Aggarwal
Dr. Anil Garg

Published by:
Forensicwayout
Dr. R. K. Gorea
#4, CharanBagh, Patiala 147001 Punjab, India
Phone number: +919872020840
Email: gorea_r@yahoo.com

Printed at:
Zenith Design World,
22 No. Phatak, Patiala 147001 Punjab India
Phone number: +919872666799
Email: zafar.zenith@gmail.com

ISSN Numbers:
ISSN-L: applied for
P- ISSN: 2394 - 6822
e-ISSN: 2395 – 4272

International Journal of Ethics, trauma & victimology (Online)
Available online at
http://ethicstraumavictimology@org
http://www.myresearchjournals.com/index.php/IJETV/
http://ijetv.forensicwayout.org/

Indexed with:
Citefactor at:http://www.citefactor.org/journal/index/11666/international-journal-of-ethics-trauma-victimology

Ulrichswebat:
https://ulrichsweb.serialssolutions.com/search/1467065051

The volume of Distribution:
1000 copies

Review Process
It is a peer-reviewed journal. The double-blind review process is followed.

Funding Bodies:
Support by SPIC &donations from philanthropists and advertisements in the journal

Address for submission of articles:
Dr. RK Gorea,
College of Medicine
Salman bin Abdulaziz University, PO. Box 173, Alkharj, 11942, Kingdom of Saudi Arabia

Online submission at
Email: editoretv@gmail.com

Address request for areprint or further information relating to any article may please be made with author and in thecase of multi-author, please communicate with the first author.

Copyright
No part of this publication may be reprinted or republished without the prior permission of Editor in chief of International Journal of Ethics, Trauma & Victimology. Submission of all papers to the journal is understood to imply that it is not being considered for publication elsewhere. Submission of amulti-authored paper implies that the consent of each author has been obtained. In this journal, every effort has been made not to publish any inaccurate or misleading information. However, the Editor and Associate Editors accept NO LIABILITY in consequences of such statements.

Subscription Information
Rs 1200 (Abroad US$ 120 or Equivalent)/issue)
Subscription should be addressed to Dr. Rakesh Kumar Gorea, Editor in Chief International Journal of Ethics, Trauma & Victimology payable at PO Box 173, Al Kharj, 11942, College of Medicine, Kingdom of Saudi Arabia.

Claims for missing issues
A copy will be sent to subscriber provided the claim is made within 2 months of issue of the journal and self-addressed envelope of the size of 9”x12” duly stamped is sent to the editor in chief (those of who want the journal to be dispatched byregistered mail should affix appropriate Stamps)

INTERNATIONAL JOURNAL OF ETHICS, TRAUMA & VICTIMOLOGY

A peer-reviewed journal Indexed with CiteFactor& Ulrichsweb

Volume 2 Number 2 June-Dec, 2016 Pages 1-48

Contents

IJETV

A Half-Yearly Publication
Volume 2(2), 2016

Department of Forensic Medicine and Toxicology
College of Medicine
Prince Sattam Bin Abdulaziz University
Kingdom of Saudi Arabia

Editor-in-Chief: Prof. Rakesh K Gorea

From Editor's Desk

The editorial board is presenting you the 2nd issue of this journal for the year 2016. With this issue, we are completing the first two successful years of publication in time. It is all due to the immense contribution of the authors, editors, and reviewers who have spent their valuable time and efforts to achieve this. I sincerely appreciate this and congratulate all of them.

It is a matter of great pleasure that this journal is getting a good response from different countries and different parts of the world and we are getting contributions from authors based in different countries and all this is due to efforts of our editors and hope that this trend will continue and increase in future.

I sincerely appreciate the contributions made by the Middle East Wing of the Society for prevention of Injuries and Corporal Punishment (SPIC) and Dr. Pardeep Singh to help in the printing of this journal.

RK Gorea

Editorial

Bullying in schools: Epidemiology and prevention

Citation: Gorea RK. Bullying in schools: epidemiology and prevention.*Int J Eth Trauma Victimology 2016*; 2(2):6-9. doi: 10.18099/ijetv.v2i02.6853

Abstract

Bullying is seen in different spheres of life but is more worrisome in schools because deleterious effects are more pronounced in victims of bullying at schools due to the young age of the victims. Different forms of bullying are observed but their effects are mostly similar though their severity varies depending on the attitude of the bullied student. Some places in any school are more prone to incidences of bullying and these areas should be specially taken care of to prevent bullying. Various strategies are adopted depending upon research in a particular institution or state but the involvement of all stakeholders is important to reduce the incidences of bullying.

Keywords: Bullying, schools, victimology, prevention

©IJETV. All rights reserved

Introduction

"Bullying is repeated verbal, physical, social or psychological behavior that is harmful and involves the misuse of power by an individual or group towards one or more persons (1)." This definition describes that the act has to be repetitive and be harmful, to be called as bullying and if did just once is not included in the bullying. This harassment can lead to a variety of consequences which is harmful and deleterious for the development of a student. This bullying involves different ways to torment a student but all leads to degradation and loss of self-respect.

It is an international problem and not confined to a few nations (2) and is a critical issue for the youth internationally (3). It is important to know about the different ways by which a student can be bullied, where the students are bullied, why they are bullied, what the consequences of bullying are and what we can do to prevent the bullying.

Review of literature

Bullying is one variety of violence and abuse of human rights (4) which can lead to physical or psychological damage (1),(4), impair the social, moral, psychological and physical development (4). and also hampers relaxation and enjoying (4). Psychological symptoms are reported 7.5 times higher in bullied children as compared to non-bullied children (5).

A single act of intimidation or aggressiveness or mutual conflict cannot be called bullying (1). Usually, there is a power imbalance between the victim and the offender and this power imbalance may be physical, in popularity or in the knowledge of embarrassing information (6). It looks apparently that power imbalance will be more in males but it is astonishing that females are bullied more as compared to males (7),(8).

Bullying is observed in various places like workplaces and schools (9). In schools usually, it occurs in playgrounds, school buses and in the buildings (6). The largest number of cases of bullying were seen in staircases or hallways 45.6% followed by bullying in classes-rooms 33.6%, school grounds 22.9%, cafeteria 18.9%, followed by bathroom 9.1% and school bus 7.8% and other places of school were just 0.8% (7).

Racial differences were seen in the victims of bullying (7),(8). It was seen more in native American and African American students (10). Bullying goes on increasing with increase in the standard of study; seen least in standard 6th (72.2%) and maximum in standard 12th (85.9%) but no difference was observed due to the income of the victim or their families (7). Those students who did not have fathers were more likely to bully others (11).

Incidence in one survey in the US is reported as 20.2% (8). The incidence of bullying in the US as per another survey is 21.5% in the age group of 12-18 years out of which insult, making fun or calling names constituted the biggest group (13.6%) closely followed by making students subject of rumours (13.2%); pushed, shoved, tripped or spit on in 6.0% or threatened with harm in 3.9%; excluded from activities in 4.5% or asked students to do things which they did not like in 2.2% or purposefully destroyed the properties of other students in 1.6% cases (7). It may be in the form of forced confinement also (5).

The majority of cases of bullying involves students 98% as compared to bullying by sibling 17%, teacher and their guardian and parents 8% in a survey done in the UK of bullied persons. A big group of the bullied persons did not report bullying (45%) because 32% considered nobody will take it seriously and a similar number felt embarrassed to report and good number thought that the situation will get worse26%. There was the maximum satisfaction of 82% when reported to a family member (86%) as compared to 72% when reported to a friend (69%) and 49% when incidence was reported to the teacher (92%) (12).

The incidence of cyber bullying becomes more when children are away from supervision by adults and are more vulnerable to consequences of cyber-bullying (13). In a survey in USA 6.9% students were cyberbullied and unwanted text messaging topped in cyberbullying at a rate of 3.2% followed by putting hurtful information on net 2.8%, unwanted contact via online, unwanted contact via instant messaging in 2.1%, gaming 1.5% sharing private information purposefully or unwanted contact via email or purposeful exclusion from an online community in 0.9% each (7). Cyber-bullying is also known as electronic bullying (5).

Though some people argue that bullying is part of growing up and is an experience (4) yet it can never be justified because it is a breach of the right to education (4). It leads to various bad outcomes in the form of low self-esteem, insecurity, withdrawal from the society, aggressive behavior,drug and alcohol abuse and various mental disorders (5). Offenders were mostly suffering from poor academic achievements (3), aggression, and substance abuse while victims were associated with depression (10) and bullying is associated with poor psychosocial adjustment (3). There are defenders of victims of bullying and passive onlookers. Pro-bullying behavior is associated with tobacco and alcohol use and even defenders behavior is related to tobacco use and alcohol use (14). There is a relationship between victimization of bullying and direct self-injuriousbehavior(15). The most serious repercussions of the bullying come in the form of deaths of the victims of bullying (10),(16).

Discussion

Bullying is a big problem in the world but this is preventable. To be successful in prevention it is very important to define bullying and this definition should be a consistent definition. Another important aspect is to know the accurate prevalence rates of bullying, anti-bullying laws, and their implementation which should be reviewed annually to find out their efficacy. Evidence-based anti-bullying programs should be developed and efforts should be made to remove the stigma associated with it. Therefore evaluation of anti-bullying programs should be done regularly and social media companies should actively work towards this programs (17).

Incidences of bullying should be reported to the authorities In the institution and in turn, they should support the victims and send them to the health departments for their treatment and also counsel the offenders making them understand what harm they are causing to the growth of the children and this will help in reduction of dropout rate due to bullying (9). Usually, offenders and victims are different students and need different preventive approaches (10).

In a Canadian study, prevention study was done based upon 5 categories of bullying behaviors: establishing positive school climate, disseminating monitoring and reviewing policy, reporting and responding to bullying and involving the community and opined that that any strategy which may be good for one institution may not yield similar results in another institution due to different implementation (18). There is a need to make the whole community aware of the nature and effects of the bullying and only then prevention is possible (19).

Some skills if learned by students can be very useful for the prevention and stopping of bullying in schools. Acting with awareness and confidence, leaving the unsafe position, saying at once to stop this, seeking adult guidance if

some unkind or disrespectful remark is given, yelling stop, positive self-talking, speaking for inclusion if excluded from some activity, getting help from busy adults and using physical self-defense but as a last resort, are the skills which can help to reduce the incidences and severity of bullying (20).

Safe Schools in USA and Olweus Bullying Prevention Program (OBPP) in Norway and Canada are well-recognized programs to prevent bullying in schools (5) and are reported to have produced a significant reduction in the victimization due to bullying (21).

School-basedanti-bullying programs can effectively reduce the verbal bullying behavior(11). Early interventions reduce the negative effects of victimization and increase mindfulness and resilience (22). Arousing the empathy for the victim and condemning the behavior of the offenders by the teacher was a better method to reduce bullying than only condemning the offender, therefore the teachers should use this strategy (23). Teachers should always be involved in the implementation of antibullying programs and there should be rewards for correct use of skills by teachers and there should be positive behavioralchange interventions (24).

Conclusions

Schools must provide a safe environment free from bullying so that every child can grow and learn peacefully. Schools have a moral and legal duty to provide a bullying-free environment. Various governments of different countries are signatories to the International Human rights declarations and are duty bound to protect the society from violation of human rights in the form of bullying. A combination of different strategies may be adopted, implemented and assessed to find out what is working best in a particular institution and modified after assessing to make it working to produce the best results.

Comments

The problem of bullying is not a well-recognized problem in all the schools in spite of its being very common. Many institutions remain in a denial mode due to the stigma associated with it. It is important to recognize this problem and make teachers, students and parents well aware of the problem and its consequences. There is urgent need to detect and act immediately after it is reported by the student. For early detection, Closed Circuit Television Cameras should be installed at places which have been reported to be frequently misused in bullying incidences. Prevention can save harmful effects of bullying and make the schools safe places where the rights of students for safe education, will never be violated.

Conflict of interest

None

Dr. RK Gorea
Editor in Chief

References

1. A definition of bullying [Internet]. NSW Government/Education Public Schools. 2014 [cited 2016 Dec 8]. Available from: http://www.schools.nsw.edu.au/studentsupport/bullying/definition/
2. Craig W, Harel Y. Bullying, physical fighting and victimization. In Currie et al. (Eds.), Young people's health in context: Health Behaviour in School-aged Children (HBSC) study: international report from the 2001/2002 survey. World Health Organization; 2004.
3. Nansel T, Craig W, Overpeck M, Saluja G, Ruan W. Cross-national consistency in the relationship between bullying behaviors and psychosocial adjustment. Arch Pediatr Adolesc Med. 2004;158(8):730–6.
4. Bullying - know your rights: Violence, harassment and bullying fact sheet [Internet]. Australian Human Rights Commission. 2016 [cited 2016 Dec 8]. Available from: https://www.humanrights.gov.au/bullying-know-your-rights-violence-harassment-and-bullying-fact-sheet
5. Bullying in Canada: How intimidation affects learning [Internet]. Canadian council of learning; 2008 [cited 2016 Dec 13]. (Lessons in learning). Available from: http://en.copian.ca/library/research/ccl/bullying_in_canada/bullying_in_canada.pdf
6. Bullying Definition [Internet]. Stopbullying.gov. [cited 2016 Dec 12]. Available from: https://www.stopbullying.gov/what-is-bullying/definition/

7. Student reports of bullying and cyber-bullying:Results from 2013 school crime supplement to the National crime victimization survey [Internet]. US Department of Education; 2015 Apr [cited 2016 Dec 10]. (Web tables). Report No.: NCES 2015-056. Available from: http://nces.ed.gov/pubs2015/2015056.pdf
8. Youth Risk Behavior Surveillance — United States, 2015 [Internet]. U.S. Department of Health and Human Services Centers for disease control and prevention; 2016 Jun [cited 2016 Dec 9] p. 10. (Surveillance Summaries). Report No.: 65(6). Available from: http://www.cdc.gov/healthyyouth/data/yrbs/pdf/2015/ss6506_updated.pdf
9. Srabstein J, Leventhal B. Prevention of bullying-related morbidity and mortality: a call for public health policies. Bull World Health Organ. 2010;88:403.
10. Carlyle K, Steinman K. Demographic differences in the prevalence, co-occurrence, and correlates of adolescent bullying at school. J Sch Health. 2007;77(9):623–9.
11. Naidoo S, Satorius B, de Vries H, Taylor M. Verbal bullying changes among students following an educational intervention using the integrated model for behavior change. J Sch Health. 2016;86(11):813–22.
12. The annual bullying survey 2015:UK bullying statistics 2015 [Internet]. Ditch the label your world prejudice free. 2016 [cited 2016 Dec 12]. Available from: http://www.ditchthelabel.org/the-annual-bullying-survey-2015-is-here/
13. Chehab Y, Levasseur C, Bowen F. From school to cyberspace: the state of research and intervention in online peer bullying. Mcgill J Educ. 2016;51(1):495–515.
14. Quinn C, Fitzpatrick S, Bussey K, Hides L, Chan G. Associations between the group processes of bullying and adolescent substance use. Addict Behav. 2016;62:6–13.
15. Klomek A, Snir A, Apter A, Carli W, Wasserman C, Hadlaczky G, et al. Association between victimization by bullying and direct self injurious behavior among adolescence in Europe: a ten country study. Eur Child Adolesc Psychiatry. 2016;25:1183–93.
16. Bernasconi C. Chile schools to get state help to fight bullying, The Santiago Times, 13 October 2008. The Santiago Times [Internet]. 2008 Oct 13 [cited 2010 May 6]; Available from: http://www.santiagotimes.cl/index.php?option=com_content&view=article&id=14859:CHILE-SCHOOLS-TO-GET-STATE-HELP-TO-FIGHT-BULLYING&catid=31:editorial-and-opinions&Itemid=143
17. Flannery D, Todres J, Bradshaw C, Amar A, Graham S, Hatzenbuehler M, et al. Bullying prevention: a summary of the report of the national academies of sciences, engineering, and medicine. Prev Sci. 2016;17:1044–53.
18. Roberge G. Countering School Bullying: An Analysis of Policy Content in Ontario and Saskatchewan. Int J Educ Policy Leadersh. 2011;6(5):1–14.
19. Srabstein J, Joshi P, Due P, Wright J, Leventhal B, Merrick J, et al. Prevention of public health risks linked to bullying: a need for a whole community approach. Int J Adolesc Med Health 2008; 20: 185-99. Int J Adolesc Med Health. 2008;20:185–99.
20. Face bullying with confidence: eight kidpower skills We can use right away [Internet]. Kidpower Take Charge of Your Safety. 2012 [cited 2016 Dec 11]. Available from: https://www.kidpower.org/library/article/prevent-bullying/?gclid=Cj0KEQiA7K7CBRCrwt26v5uHs98BEiQA0JzsZ_3wuOgjT-sUz4RVo4Q9tAj69z2m6i9JEZjxOv7Rq20aAobU8P8HAQ
21. Vreeman R, Carroll A. A systematic review of school-based interventions to prevent bullying. Arch Paediatr Adolesc Med. 2007;161:78–88.
22. Zhou Z, Liu Q, Niu G, Sun X, Fan C. Bullying victimization and depression in Chinese children: A moderated mediation model of resilience and mindfulness. Personal Individ Differ. 2017;107:137–42.
23. Garandeau C, Vartio A, Poskiparta E, Salmivalli C. School bullies' intention to change behavior following teacher interventions: effects of empathy arousal, condemning of bullying, and blaming of the perpetrator. Prev Sci. 2016;17:1034–43.
24. Letendre J, Ostrander J, Mickens A. Teacher and staff voices: implementation of a positive behavior bullying prevention program in an urban school. Child Sch. 2016;38(4):235–43.

Is the manner of suicide predetermined? – Gastric contents can reveal the truth

Dr. Saurabh Chattopadhyay, Professor and Head, Department of Forensic Medicine, Malda Medical College, Malda,West Bengal, India.
Dr. Aloke Mazumdar, Assistant Professor, Department of Forensic Medicine, Malda Medical College, Malda,West Bengal, India.
Dr. Rubal Gangopadhyay, Demonstrator, Department of Forensic Medicine,Murshidabad Medical College, Berhampore,West Bengal India.

Citation:Chattopadhyay S, Mazumdar A, Gangopadhyay R. Is the manner of suicide predetermined? – Gastric contents can reveal the truth. *Int J Eth Trauma Victimology 2016*; 2(2):10-13. doi: 10.18099/ijetv.v2i02.6854

Article history

Received: September 25, 2016
Received in revised form: Dec11, 2016
Accepted: Dec18, 2016
Available online: Dec28, 2016

Corresponding author

Dr. Saurabh Chattopadhyay
Professor and Head, Department of Forensic Medicine, Malda Medical College, Malda,West Bengal, India.

Phone:+919433968710
Email: chattopadhyaydrs@rediffmail.com

Abstract
Suicidal deaths have been reported from across the world in different communities, religion, and socio-economic groups. In the developing countries, irrespective of the reason for such deaths the manners of suicide are usually by means of poisoning, hanging, burn or drowning. Rarely gunshot injuries or fall from height are resorted to. The present study aims to determine the different methods opted for suicide in a rural setting in West Bengal. Out of the 134 cases studied over a period of 2 years, hanging was the most common method among both sexes followed by poisoning. In the majority of the cases of hanging food was detected in the stomach while in cases of poisoning it was found only in 39.1% cases. This indicated the knowledge of the victims that food might interfere with the actions of poison and hence to avoid it before consumption of the toxic substance. The presence or absence of the gastric contents also points out towards the predetermined mindset of the deceased with regards to the choice of the method of suicide.

Keywords:Suicide; manner; gastric contents; predetermined.

© IJETV. All rights reserved

Introduction

Suicidal deaths are a common mode of unnatural death in the present society. Irrespective of age, sex, and socio-economic status, such incidents have been reported throughout the globe. The reasons for suicide may vary depending on the age, sex, and society. Suicidal attempts may be committed in the heat of the moment as an impulsive act resulting from a sudden emotional instability due to an untoward incident(1). Psychological stress due to familial disharmony, failure in love, financial hardship or torture may also lead to such deaths(2),(3),(4). Aliamo et.al.were of the opinion that family food insufficiency and not family income was positively associated with suicides(5). The choice of the manner of suicide e.g. hanging, poisoning, burn etc. is difficult to predict in such victims. Prolonged depressive episodes affect the appetite of the subjects and usually, they reduce their food intake or remain starved prior to the incident(6). The present study aims to determine the different manners of suicide in a rural population in west Bengal, India and whether the choice of the manner is predetermined by the victims or not.

Methods

The present study was conducted between January 2014 and December 2015. A total of 134 cases of suicidal deaths were included in the study. Only those suicidal cases which were declared brought dead at the hospital or expired within a very short period of admission without any medical

intervention being possible were included in the study. Details regarding the victims were obtained from the family members and inquest report. Standard autopsy procedures were followed for dissection. The stomach contents were carefully examined for the presence of food and any suspicious or poisonous substance. Only those poisoning cases with definitive findings on autopsy were included in the study. The data collected were analyzed using SPSS 16.

Results

A total of 134 suicidal cases were studied during the 2 year period out of which 68 were males and 66 females.

Table 1: The different manners of suicide and its gender distribution

Manner of suicide	Gender		Chi-square at df 2, p-value
	Male	Female	
Hanging (n_1 =77)	41(53.25%)	36(46.75%)	2.66, 0.265
Poisoning (n_2=46)	24(52.17%)	22(47.82%)	
Burn (n_3=11)	3(27.27%)	8(72.72%)	
Total (N=134)	68(50.75%)	66(49.25%)	

Table 1. Hanging was the most common manner of suicide (n=77, 57.5%) among both sex (males -53.2%, females-46.7%) followed by poisoning (males52.1%, females47.8%). The manner of suicide was found to have no variations across the gender of the deceased.

Table 2: Stomach contents in cases of suicide

Manner of suicide	Stomach contents		Chi-square at df 2, p-value
	Food particles	Empty	
Hanging (n_1 =77)	47(61.04%)	30(38.9%)	5.56, 0.062
Poisoning (n_2=46)	18(39.13%)	28(60.9%)	
Burn (n_3=11)	6(54.55%)	5(45.5%)	
Total (N=134)	71(52.99%)	63(47.1%)	

Table 2.in nearly 53% cases the food was detected in the stomach of the deceased. In the case of hanging majority (61.1%) of the victims had food in their stomach while in poisoning it was found only in 39.1% cases. In the case of burns also the presence of food was detected in more than half of the victims.

Table 3: Comparison of stomach contents among hanging and poisoning cases

Manner of suicide	Stomach contents		Chi-square at df 1, p-value	OR (95% CI)
	Food particles	Empty		
Hanging (n_1 =77)	47 (61.04%)	30(38.9%)	5.55, 0.0185	2.44 (1.08-5.53)
Poisoning (n_2=46)	18(39.13%)	28(60.9%)		
Total (N=123)	65(52.85%)	58(47.1%)		

Table 3. Considering the suicidal cases of poisoning and hanging which consisted majority of the cases in our study, it can be said that higher number of deceased of hanging were found to contain food particles in their stomach compared to that of poisoning group and the difference was statistically significant.

The weight of the stomach contents in those cases where it was detected varied between 120 grams to 480 grams.

Discussion

A number of studies throughout the world have shown that under consumption of fruits, vegetables and meat(7), low level of cholesterol(8) and low antioxidant vitamins (9)are associated with increased risk of a suicidal attempt.

In our study, there was no variation in the manner of suicide among both sexes. Hanging was the preferred manner than poisoning or burns. Though the study population in the present study was from a rural background yet hanging was the preferred

mode than poisoning. This may be due to the fact hanging causes early death and is less painful compared to poisoning. It also shows that the victims were determined to terminate their life and did not want to take any chances as the possibility of survival following medical intervention in poisoning might not fulfill their purpose. Soman etal.in a community-based study in Kerala also reported hanging (64%) to be the commonest mode of suicide followed by poisoning (10%), drowning (9.3%) and burns (6.4%)(10).

In the majority of the cases of hanging (61.1%) and burns (54.5%), the food was detected in the stomach on autopsy whereas in poisoning only 39.1% cases had food. This shows that most of the victims who committed suicide by poisoning avoided food before the attempt as they might be having the knowledge that the presence of food in the stomach would make the poison less effective.

When the two common groups in our study – hanging and poisoning were compared regarding the presence of food in the stomach, the difference was found to be significant. Thus those individuals who opted for hanging as the mode of suicide can be said to be having a predetermined idea regarding the choice of manner as they consumed food and knew that it would not affect in the process of hanging. The same holds true also for those who opted for poisoning. As they were predetermined to commit suicide by poisoning hence majority of them avoided food prior to the attempt. The time of incidence among the two groups was also studied but did not show any significant variation. Kibayashi(11) in their study reported that food was detected in the stomach in 41.1% cases of suicidal drowning.

Hence the present study shows that even in the rural areas with poor educational level people have the knowledge that food might interfere with the poison and so it was mostly consumed in empty stomach or mixed with some liquid. It can also be opined that the choice of the method for committing suicide is predetermined to some extent. Those who opt for poisoning usually avoid food before the attempt while those who opt for other methods like hanging or burn do not. Thus contrary to the common belief that most of the suicides are committed suddenly at the heat of the moment in a sudden outburst of emotional stress, it can be said beyond any doubt that most such incidents are predetermined with regards to their choice of the manner of suicide.

Conclusion

Hanging was the most common manner of suicide among both sexes in spite of the victims being from rural areas. The earlier and less painful death in hanging made it the preferred choice. On examination of the stomach contents and the method of suicide, it was evident that the individuals had the knowledge that food might interfere with the effects of the poison. Presence or absence of food in the stomach on autopsy proved that the manner of suicide was predetermined in most cases regarding whether it would be by poisoning or by other means.

Acknowledgment

The authors express their sincere thanks to Dr. TK Sarkar, Associate Professor, Department of Community Medicine, Murshidabad Medical College, Berhampore for his help and support in thestatistical analysis of the cases.

Conflict of Interest

None.

Funding

None.

References

1. Brezo J, Paris J, Turecki G. Personality traits as correlates of suicidal ideation, suicide attempts, and suicide completions: a systematic review. Acta Psychiatr Scand. 2006;113(3):180–206.
2. Manoranjitham S, Rajkumar A, Thangadwai P, Prasad J, Jayakaran R, Jacob K. Risk factors for suicide in rural South India. Br Jr Psychiatry. 2009;196(1):26–30.
3. Prasad J, Abraham VJ, Minz S, Abraham S, Joseph A, Muliyil JP, et al. Rates and factors associated with suicide in Kaniyambadi block, Tamil Nadu, South India, 2000–2002. Int J Soc Psychiatry. 2006;52(1):65–71.
4. Gururaj G, Isaac MK, Subbakrishna DK, Ranjani R. Risk factors for completed suicides: A case-control study from Bangalore, India. Inj Control Saf Promot. 2004;11(3):183–91.
5. Alaimo K, Olson CM, Frongillo EA. Family food insufficiency, but not low family income, is positively associated with dysthymia and suicide symptoms in adolescents. J Nutr. 2002;132(4):719–25.
6. Song H-B, Lee S-A. Socioeconomic and lifestyle factors as risks for suicidal behavior among Korean adults. J Affect Disord. 2016;197:21–8.
7. Li Y, Zhang J, McKeown RE. Cross-sectional assessment of diet quality in individuals with a

lifetime history of attempted suicide. Psychiatry Res. 2009;165(1):111–9.
8. Zhang J. Epidemiological link between low cholesterol and suicidality: a puzzle never finished. Nutr Neurosci. 2011;14(6):268–87.
9. Li Y, Zhang J. Serum concentrations of antioxidant vitamins and carotenoids are low in individuals with a history of attempted suicide. Nutr Neurosci. 2007;10(1-2):51–8.
10. Soman CR, Safraj S, Kutty VR, Vijayakumar K, Ajayan K, others. Suicide in South India: a community-based study in Kerala. Indian J Psychiatry. 2009;51(4):261–4.
11. Kibayashi K, Shimada R, Nakao K. Frequent detection of stomach contents in accidental drowning. Med Sci Law. 2011;51(3):161–3.

Age estimation from the fusion of distal end of fibula epiphysis

Dr. Pardeep Singh, Prof, Teerthankar Mahaveer Medical College, Moradabad, UP, India.
Mrs. Davinder Kaur, PG Tutor, Teerthankar Mahaveer Nursing College, Moradabad, UP, India.
Dr. R.K. Gorea, Faculty Member, College of Medicine, Prince bin Abdulaziz Sattam University, Al Kharj, Kingdom of Saudi Arabia
Dr.S.S. Oberai, Additional Prof, GMC, Patiala, India.
Dr. A. K. Kapila, Prof (Retd.), Department of Radiodiagnosis, GMC, Patiala, India.

Citation: Singh P, Kaur D, Gorea RK, Oberai SS, Kapila AK. Age estimation from the fusion of distal end of fibula epiphysis. *Int J Eth Trauma Victimology 2016*; 2(2):14-17. doi: 10.18099/ijetv.v2i02.6855

Article history

Received: April25, 2016
Received in revised form: Oct11, 2016
Accepted: Oct25, 2016
Available online: Dec28, 2016

Corresponding author

Dr. Pardeep Singh
Professor, Teerthankar Mahaveer Medical College, Moradabad, UP, India.

Phone:+918397952319
Email: drpardeepsingh@yahoo.com

Abstract
The range of variation in epiphyseal fusion for the distal end of fibula epiphysis in Punjab, India populations has been studied in the present study. This study evaluates epiphyseal fusion of the distal fibula in 100 young individuals, 50 males, and 50 females with age range from 16-17 years to 24-25 years. Radiographs were performed at Rajindra Hospital, Patiala, Punjab, India with 10 cases from each age group in both males and females. Both AP and lateral views of X-ray were taken. Results indicate that complete fusion in males occur at the age of 18-19 age group and in females occurs at 16-17 year age group in the distal end of the fibula. Earliest union for males and females occur at 16 years.

Keywords- Epiphyseal fusion, x-ray, age estimation, fibula.

© IJETV. All rights reserved

Introduction

Determination of age in Indian population is very important now a day due to changes in age for various crimes. Epiphysis of the bones unites at the particular age which is remarkably constant for a Particular epiphysis and this is helpful in age determination (1). Age is helpful in identification of an individual which in turn is helpful in both civil and criminal cases as per Sangma (2). Study of the epiphyseal union of bones is considered a reasonably accurate and accepted method for age determination by the law courts all over the world (3). According to Modi's textbook, due to variation in climatic, dietetic, hereditary and other factors affecting the people of the different states of India, it cannot be reasonably expected to formulate a uniform standard for the determination of the age of the union of epiphyses for the whole of India (4). Union of epiphysis in cartilaginous Bones takes place earlier in the females by about 2 years than in males except in the case of skull Sutures where obliteration sets in little later and proceeds more slowly in females than in males and Under tropical conditions ossification is observed earlier than in temperate areas (5). With the onset of decomposition, the identification becomes difficult and so one has to rely more and more on the scientific methods available (6). While There are a number of studies on morphological and metrical variation in the tibia (Wood 1920; Hanihara 1958; Steel 1972; Iscan and Miller Shaivitz 1984; Iscan et al. the fibula has been largely ignored (7).

In an American study, complete fusion of distal end of fibula occurred as early as 12 years in females and completed by 16 years, and as early as 14 years in females and completed in 19 years (8). This fusion can also be observed by ultrasonography as this process is radiation free and by this method, complete fusion was observed by 18 years (9).

To narrow the wide age range union of the epiphysis of bones in the present study is done with the help of fusion of epiphysis in the distal end of the fibula. Age of each individual studied was confirmed from

the birth certificate, service record, driving license, passport, ration card or voter's card etc.

Material and Methods

In the present study, 100 cases were studied including male and female differently. The cases studied were between the age group of 16-25 years that were exposed to x-ray at Rajindra Hospital Patiala. Male and female individuals were studied with age interval of two years and ten cases from each age interval were taken. The cases were studied with the help of X-ray Ankle joint-anteroposterior view for the distal end of the fibula.

Status of epiphyseal union was divided into following four stages:

Stage	Grade	Appearance and fusion
I	A	Centre not appeared
II	+	Centre appeared but no union
III	++	Union started but incomplete
IV	+++	Complete union

Method for X- Ray examination

The study has been carried out by Roentgenographic technique.

The technique included standardization of -

1. Time of exposure, 2. Positioning of the part, 3.Distance of film from X- Ray tube and
4. Processing and time of developing the films.

The positioning of the epiphysis during X- ray examination- Clark's radiographic technique has been followed in this investigation.

AP view for Ankle joint -Positioning of Patient and Film

The patient should be lying supine or seated with support and with a small sandbag under the knees to allow slight flexion for comfort. A non-opaque pad under the tendo-calcaneus serves to prevent discomfort due to the pressure of the heels on the couch. The ankle is supported in dorsiflexion and the limb rotated medially until the medial and lateral malleoli are equidistant from the film thus ensuring a clear joint space on the radiograph between tibia fibula and talus. A 90-degree angle block supported by sandbags is used to maintain the foot in position. The film size should be large enough to include the lower third of the leg. The foot is placed so that its plantar aspect is at level with the lower edge of the cassette. Direction and Centering of the X- ray Beam; Centre midway between the malleoli with the central ray at right angles to an imaginary line joining the malleoli.

Results

The incidence and extent of fusion of the distal end of the fibula in different age groups studied in the present investigation was as follows:

Table 1: Extent of fusion in different age groups in males

Extent of fusion	Age Group 16-17 years		Age Group 18-19 years		Age Group 20-21 years		Age Group 22-23 years		Age Group 24-25 years	
	Cases	%age	Cases	% age	Cases	% age	Cases	% age	Cases	% age
Centre not appeared	0	0	0	0	0	0	0	0	0	0
Centre appeared but no union	3	30	0	0	0	0	0	0	0	0
Union started but incomplete	2	20	0	0	0	0	0	0	0	0
Complete union	5	50	10	100	10	100	10	100	10	100

The above table show in the age group 16—17 years, in three cases (30 %) center appeared but no union occurred, in 2 cases (20 %) c union started but incomplete & in five cases (50%) complete union occurred.

In the age group 18—19 years, 20—21 years, 22—23 years & 24-25 years, in ten cases (100 %) complete union occurred.

Table 2: Extent of fusion in different age groups in females

Extent of fusion	Age Group 16-17 years		Age Group 18-19 years		Age Group 20-21 years		Age Group 22-23 years		Age Group 24-25 years	
	Cases	%age	Cases	% age	Cases	% age	Cases	% age	Cases	% age
Centre not appeared	0	0	0	0	0	0	0	0	0	0
Centre appeared but no union	0	0	0	0	0	0	0	0	0	0
Union started but incomplete	0	0	0	0	0	0	1	10	0	0
Complete union	10	100	10	100	10	100	9	90	10	100

Table no. 2 shows in the age group 16—17 years, 18—19 years, 20—21 years & 24-25 years, in ten cases (100 %) complete union occurred.

In the age group 22—23 years, in one case (10 %) union started but incomplete & in nine cases (90%) complete union occurred.

Discussion

Table 3: Comparison of time of fusion findings (in years) shown by different authors

Author	Year	Race	Sex			Earliest Union(years)
			Male	Female	Mixed	Male/Female
Hepworth (10)	1929	Punjab (India)	-	-	17-18	
Pillay (11)	1936	Madrassies (Indian)	-	-	14-17	-
Galstaun (12)	1937	Bengalis (Indians)	14-16	13-15	-	-
Basu & Basu (13)	1938	Bengalis (Indians)	-	-	15	
Krogman (7)	1962	U.S.A.	-	-	15.6-16.6	-
Parikh (14)	1990	Indian	-	-	16-18	-
Krishan Vij (15)	2001	Indian	-	-	16-17	-
Dr.S.Patond et al (16)	2012	Indian	15-16	15-16		
Present	2004	Punjab (Indian)	18-19	16-17	-	M = 16 F = 16

Time of fusion of distal end of fibula: Findings are in confirmatory with Krishan Vij for females only.

Age of earliest Union: Stevenson gave 17 years for the earliest union, which was not in confirmatory

Findings are not in confirmatory with anyone for males.

with the present study.

The Findings in the present study are closer to Hepworth (10) and Krogman (7).

Hepworth (10) and Vij (15) used male and female individuals (mixed).

Table 4: Age of incidence of complete union found to be as follows

Age Group (Years)	Total No. of cases examined	For Males No. of cases showing complete union	%age	For Females No. of cases showing complete union	%age
16-17	20	5	50	10	100
18-19	20	10	100	10	100
20-21	20	10	100	10	100
22-23	20	10	100	9	90
24-25	20	10	100	10	100

Table no. 4 shows for males in 16-17 years age group five cases (50%) show complete union, in 18-19, 20-21, 22-23 and in 24-25 years age group all ten cases (100%) show complete union.

Conclusions

Epiphysis of the distal end of fibula fused in the majority of cases at 18-19 years in males and 16-17 years for females. Earliest union occurred at 16 years in both male and female. Findings are in confirmatory with Vij (15) for females only. Stevenson gave 17 years for the earliest union, which was not in confirmatory with the present study.

References

1. Aggarwal A. Ages of ossification-Personal Identification in Self Assessment and Review of Forensic Medicine and Toxicology. 1st ed. Delhi: Peepee Publishers and Distributers (P) Ltd; 2006. 51-59 p.
2. Sangma W, Marak F, Singh M, Kharrubon B. Age determination in girls of north – eastern region of India. J Indian Acad Forensic Med. 2007;29(4):102–8.
3. Banerjee K, Aggarwal B. Estimation of age from epiphyseal union at the wrist and ankle joint in the capital city of India. Journal of Forensic science International. J Forensic Sci Int. 1998;98:31–9.
4. Subrahmanyam B. Modi's Medical Jurisprudence and Toxicology. 22nd ed. New Delhi: Butterworth's India; 1999. 52-58 p.
5. Parikh C. Parikh's Textbook of Medical Jurisprudence and Toxicology. 6th ed. New Delhi: CBS Publishers and distributors; 1996. 2.8-2.14 p.
6. Oberoi S. To study anthropometric measurements of adult skull for determination of sex and stature in Rohtak (Haryana). [Rohtak]: Maharishi Dayanand University, ,; 1986.
7. Krogman W. The Human skeletal in Forensic Medicine,. 1st ed. Charles C Thomas Pub Ltd; 1962. 18-71, 76-89, 92-111 p.
8. Mehta H. Age determination-Medical Law and Ethics in India. The Bombay Samachar Pvt. Ltd. .(cited in chapter Personal Identity in chapter Personal Identity in Modi's Medical Jurisprudence and Toxicology. Mumbai; 1963.
9. Jit J, Kulkarni M. Time of appearance and fusion of epiphysis at medical end of clavicle. Indian J Med Res. 1976;64(5):773–82.
10. Hepworth S. On the determination of age in Indians, from a study of the ossification of the epiphyses of the long bones. Ind Med Gaz. 1929;64:128.
11. Pillay V. Forensic Medicine, Textbook of Medical Jurisprudence and Toxicology. 14th ed. Hyderabad: Paras Publishing; 2004. 62-69 p.
12. Galstaun G. Ind Jour Med Res. 1937;25:267.
13. Basu S, Basu S. Medicolegal aspects of determination of age of Bengali girls. Ind Med Res. 1938;58(4):97.
14. Parikh C. Parikh's Textbook of Medical Jurisprudence and Toxicology. 5th ed. New Delhi: CBS Publishers and distributors; 1990. 39-50 p.
15. Vij K. Textbook of Forensic Medicine, Principle and Practice. 1st ed. New Delhi: B.I. Churchill Livingston; 2001. 74-82 p.
16. Patond et al S. Age determination from epiphyseal union of bones at ankle joint in girls of central India. J Forensic Med Sci Law. 2012;21(2).

Ethics In Orthodontics: A Retrospective review

George Sam MDS [Orthodontics], Lecturer, Department of Preventive Dental Sciences, College of Dentistry, Prince Sattam bin Abdul Aziz University, Al Kharj, Kingdom of Saudi Arabia.
Ziyad A Alaskar, Department of Preventive Dental Sciences, College of Dentistry, Prince Sattam bin Abdul Aziz University, Al Kharj, Kingdom of Saudi Arabia.
Mohammed Ali Salem Abu Elqomsan M.Sc. [Operative Dentistry], Lecturer, Department of Operative Dentistry and Endodontics, College of Dentistry, Prince Sattam bin Abdul Aziz University, Al Kharj, Kingdom of Saudi Arabia.
Mohammed A. Alateeg, Department of Operative Dentistry and Endodontics, College of Dentistry, Prince Sattam bin Abdul Aziz University, Al Kharj, Kingdom of Saudi Arabia.

Citation:Sam G, Alaskar ZA, Elqomsan MASA, Alateeg MA. Ethics In Orthodontics: A Retrospective review. *Int J Eth Trauma Victimology 2016*; 2(2):18-20. doi: 10.18099/ijetv.v2i02.6856

Article history

Received: September 25, 2016
Received in revised form: Dec 11, 2016
Accepted: Dec 18, 2016
Available online: Dec 28, 2016

Corresponding author

George Sam, Lecturer, Department of Preventive Dental Sciences, College of Dentistry, Prince Sattam bin Abdul Aziz University, Al Kharj, Kingdom of Saudi Arabia.

Phone:+966553249548
Email: orthodonticsindia@gmail.com

Abstract

When treating a patient in an orthodontic clinic, significant ethical issues may arise unfolding to the best interests of the patient and decision making for them. The case of a patient with a cleft lip and palate whose parents failed to bring her in for medically indicated orthodontic care is offered. Ethical features of the case are discussed, including the need to benefit the patient, avoid harm, and respect the preferences of the parents. Ethical codes of the American Dental Association and American Medical Association are referenced. Ethical dilemmas include the variance between the orthodontist's commitment to the patient and the need to value the parental autonomy. Parental independence is respected up until the point at which significant harm to a patient may result. The orthodontist's primary ethical responsibility is to the patient and not to anybody else. The orthodontist providing medically indicated care should involve the craniofacial team or hospital social worker when parental decision making is in the query.

Keywords: Ethics, Orthodontics, Treatment, Orthodontic clinic

© IJETV. All rights reserved

Introduction

Most experienced ethical dentists are attuned to their own patient's reasonable aesthetic desires and aspirations. Many have invested in further appropriate training and are more than capable, willing and able to help with improving patient's dental appearance by using sensible, biologically sound, minimally destructive, ethical means if allowed to do so. solving aesthetic problems ethically requires very detailed individual discussions and careful evaluation of the various options available (including the ones that other disciplines or skills could possibly provide) coupled with appropriate training and skills before there can be any real hope of achieving appropriate solutions to those problems (1). The number of adolescents receiving orthodontic treatment worldwide has increased considerably, and as a consequence, different techniques and morphological treatment results have frequently been studied. Nonetheless, exceptionally few research projects have looked at patient satisfaction with treatment outcome and the factors contributing to satisfaction (2). Continued existence as a dental specialty requires orthodontics' commitment to innovation and hinges on orthodontics' ability to adapt to the evolving needs of the patients being cared for, to the aspirations of new entrants in the field and to the privations of veteran practitioners entrenched in practice (3). The literature reports that 20% to 50% of all orthodontic

treatment is performed by general dentists with no certificate of specialization in orthodontics (3),(4),(5). While there is no legal basis for impeding general dentists from providing orthodontic treatment, society needs scientific parameters that allow the choice of oral healthcare professionals who are capable of providing the best care in terms of quality orthodontic treatment. Thus, knowledge of the experience of orthodontic communities in different countries can favor the proper political and administrative conduct of institutions involved in orthodontics as a science (4). Although there are ethical dimensions to all medical and dental care, orthodontic interventions were rarely been the subject of specific ethical inquiry. Orthodontists do encounter ethical dilemmas at many levels. Although orthodontist rarely deals with life or deathdecisions, important human values are at stake in the course of treatment. These include:Preventing pain, preserving and restoring oral function for normal speech and eating, andpreserving and restoring patient's physical appearance and promoting a sense of control over and responsibility for his or her own health (5). Due to the complexities of the human body, dental surgeons (DDS) are increasingly specializing in different professional areas, as already happens in the field of medicine. Dental surgeons have come to understand and internalize the need to specialize in a given field, as performing too many different procedures leaves them subject to more frequent errors, facing disgruntled patients and occasional lawsuits. Another problem currently faced by DDS is the lack of professional ethics. Unhappy with their treatment, patients seek a different professional, who due to fierce and unfair competition, seeking more clients seeking only profits makes depreciative comments regarding their "colleague" Added to all of this, the improve access to information, as the result of globalization, led people to become more aware of their rights (6) . To improve the ethical decisions in a given circumstance evidence-based ethics should be preferred over subjective ethical decisions (7).

Points to be considered to maintain orthodontics a sustainable dental specialty we have to consider 5 keys, namely:

Key 1: Applied craniofacial biology must change to dentofacial enhancement

Orthodontics must expand from applied craniofacial biology with questionable utility in a large proportion of cases to a socio-economic realm along with other enhancement services now performed and accepted by other health professionals such as plastic surgeons, dermatologists, and mental health professionals (8),(9). Orthodontists need to come to grips with the fact that we are performing quality of life enhancements and not really curing a disease.

Key 2: Handicapping malocclusion must change to classification of dentofacial traits consistent with wellness

A century after the introduction of Angle's concept of ideal occlusion as the central tenet of orthodontics and the benchmark for assessing a patient's orthodontic need, there is significant evidence in the literature challenging the validity of this hypothesis (10).The National Institute for Dental Research and the National Research Council of the National Academy of Sciences organized three independent panels to examine the research regarding the definition of malocclusion, variation in dental occlusion and handicapping orthodontic conditions(11),(12),(13).

Orthodontic conditions are a continuum of normal biological variation to developmental anomalies and by defining orthodontics as the specialized branch of dentistry concerned with variations in dentofacial traits, which may affect an individual's overall well-being, occlusion no longer becomes the sine qua non of the specialty (14).

Key 3: Duration of orthodontic residency must change from 3 years to 2 years

There is no scientific data to suggest that orthodontic residency programs greater than 24 months duration produce more capable graduates (15). As well, based on the number of unpublished versus published master's thesis in the orthodontic literature, the specialty should seriously consider the significance of this exercise in orthodontic training programs (16).

Key 4: Encouraging debt must change to requiring fiscal responsibility

It is completely irresponsible and unethical for our specialty to encourage students to incur handicapping levels of debt en route to becoming orthodontists (17),(18).

Key 5: Funding consumer marketing must change to endowing scholarships

General dentists and pediatric dentists are not the enemies. The Commission on Dental Accreditation requires teaching orthodontics didactically and

clinically in both the undergraduate dental curriculum and post-doctoral pediatric dental residency training program. Many non-orthodontists perform valuable orthodontic services to patients and to portray them to the public as ‘‘under’’ educated does not redound to our best interests as an ethical and respected dental specialty (19),(20).

Conclusion

Orthodontists need to come to grips with the actuality that we are performing quality of life enhancements and not really curing a disease and awareness of the experience of orthodontic communities in different countries can support the proper political and administrative conduct of institutions concerned in orthodontics as a science.Times change and the specialty of orthodontics is facing different challenges than it was 25 years ago. Perchance it is time to look at this predicament once again. Take a good, hard look. What is the ethical instance we are trying to set? Can we afford NOT to take a position? There is a way to make the treatment process convenient and just.

References

1. Kelleher M. Ethical issues, dilemmas and controversies in’cosmetic’or aesthetic dentistry. A personal opinion. Br Dent J. 2012;212(8):365–7.
2. Feldmann I. Satisfaction with orthodontic treatment outcome. Angle Orthod. 2014;84(4):581–7.
3. Ackerman MB. Six keys for making orthodontics a sustainable dental specialty. Angle Orthod. 2013;83(6):1102–3.
4. Marquesa LS, de Freitas Juniorb N, Pereirac LJ, Ramos-Jorged ML. Quality of orthodontic treatment performed by orthodontists and general dentists A blind comparative evaluation. Angle Orthod [Internet]. 2012 [cited 2016 Dec 16];82(1). Available from: http://invisaligncostnyc.com/wp-content/uploads/2013/06/Ortho-Vs-GPs.pdf
5. Mouradian W. Ethics of orthodontics. Angle Orthod. 1999;69(4):295–9.
6. Paranhos LR, Benedicto EDN, Fernandes MM, Queluz DDP, Daruge E, Torres FC. Ethical and legal considerations on professional liability of the orthodontist. Dent Press J Orthod. 2012;17(6):146–53.
7. Gorea RK. Evidence based medical ethics: A critical evaluation. Int J Ethics Trauma Vict. 2015;1(1):5–7.
8. Ackerman JL, Kean MR, Ackerman MB. Orthodontics in the age of enhancement. Aust Orthod J. 2004;20(2):3A.
9. Ackerman MB, Rinchuse DJ, Rinchuse DJ. ABO certification in the age of evidence and enhancement. Am J Orthod Dentofacial Orthop. 2006;130(2):133–40.
10. Ackerman JL, Ackerman MB, Kean MR. A Philadelphia fable: how ideal occlusion became the philosopher’s stone of orthodontics. Angle Orthod. 2007;77(1):192–4.
11. Moorrees CF, Burstone CJ, Christiansen RL, Hixon EH, Weinstein S. Research related to malocclusion: a “state-of-the-art” workshop conducted by the oral-facial growth and development program, the national institute of dental research. Am J Orthod. 1971;59(1):1–18.
12. Isaacson RJ, Christiansen RL, Evans CA, Riedel RA. Research on variation in dental occlusion: A “state of the art” workshop conducted by the Craniofacial Anomalies Program, the National Institute of Dental Research. Am J Orthod. 1975;68(3):241–55.
13. Morris AL, others. Seriously handicapping orthodontic conditions. Wash DC Natl Acad Sci. 1976;
14. Ackerman MB. Enhancement orthodontics: Theory and practice. Wiley-Blackwell; 2007.
15. Lindauer SJ. Is the time really right for mandatory 3-year orthodontic residency programs? Am J Orthod Dentofacial Orthop. 2008;133(1):2–3.
16. Ackerman JL. Orthodontics: Art, Science, or Trans-science? Angle Orthod. 1974;44(3):243–50.
17. Turpin DL. Debt a fact of life for postgraduate students. Am J Orthod Dentofacial Orthop. 2007;132(3):275–6.
18. Lindauer SJ. Who pays for orthodontic education? Angle Orthod. 2013;83(4):743–743.
19. Ackerman MB. Selling orthodontic need: innocent business decision or guilty pleasure? J Med Ethics. 2010;36(5):275–8.
20. American Association of Orthodontists. 2013 [cited 2013 Jul 20]. Available from: https://www.aaoinfo.org/news/2013/05/consumer-awarenessprogram-debuts-new television-commercials

Educate: Don't punish

Dr. Falak Chowdhary, Assistant Surgeon, Department of Health & Family Welfare, Jammu (J&K).India
Dr. Zoya Chowdhary, Assistant Surgeon, Department of Health & Family Welfare, Jammu (J&K). India
Dr. Aniece Chowdhary, Assistant Surgeon, Department of Health & Family Welfare, Jammu (J&K). India

Citation:Chowdhary, F, Chowdhary Z, Chowdhary. Educate: Don't punish. *Int J Eth Trauma Victimology 2016*; 2(2):21-25. doi: 10.18099/ijetv.v2i02.6857

Article history

Received: August8, 2016
Received in revised form: Dec 11, 2016
Accepted: Dec 18, 2016
Available online: Dec 28, 2016

Corresponding author

Dr. Zoya Chowdhary, Assistant Surgeon, Department of Health & Family Welfare, Jammu (J&K), India.

Phone:+ +91 9086592679

Email: dr.zoya1988@gmail.com

Abstract

We all have seen/ experienced incidences of corporal punishment, but most of us don't see them as something strange/ to question, and yet it makes us feel uncomfortable. In other words; corporal punishment is just one of the wrong ways to discipline a child. In our society, it is a trend that children in school as well as at home are physically punished if they do not conform to the set social behavior. The punishment varies from physical abuse to psychological abuse. A child responds differently to the menace of corporal punishment and the uncontrolled anger of the parent/ teacher, may result in injuries or even death of the child.

Children respect and admire adults whether parents/ teachers but these punishments may lead to anger and frustration which diminish the intimacy which the child has towards them and to cope up with the persistent abuse, the child indulges in self-destructive activities like alcohol abuse etc and even suicidal attempts. Chronic abuse of the child leads to abreachof the trust between the child and the parent/ teacher causing effects beyond physical/ mental trauma, there is anerosion of the self-esteem, fear of closeness and ill-conceived attempts to avoid unpleasant reminders of child abuse. The use of corporal punishment is strongly rooted in our society and is passed on through generations. However, this doesn't mean that corporal punishment is justified. So, putting an end to corporal punishment is our ethical duty.

Keywords: Corporal punishment, dental injuries, schools.

© IJETV. All rights reserved

Introduction

Corporal punishment is defined as "Any punishment in which physical force is used and intended to cause some degree of pain or discomfort, however, light" by the UN Committee on the Rights of the Child(1).

Corporal punishment to many people means "the use of physical pain, but not wounds, as a means of discipline" (2), or in other words; corporal punishment is just one of the wrong ways to discipline a child. Most of us don't see these punishments as something strange, something to be questioned, and yet it does make us feel uncomfortable.

We justify that Corporal punishment may be distinguished from physical abuse via two factors; Intensity of violence and Intention of the individual(2). But does that mean if a person slaps or

hits you with good intentions then you won't feel the pain or feel bad about it?

We all have seen/ experienced incidences of corporal punishment because its use is strongly rooted in our society and is passed on through generations. However, this doesn't mean corporal punishment is justified.

Why punish child

Child discipline is very important – without it, society would have many problems. So, in order to discipline children, we use corporal punishment. However, there are several reasons which come into light as to why to use corporal punishment; few of them may be;

- 'Spare the rod and spoil the child', 'Children need to be molded' 'Children Are Empty Vessels'; this is the kind of thinking which still persist in our society. We think it is appropriate to child education and also it will give achild a bright future. But it is on a contrary the other way round(2).
- The person lacks sufficient resource to tackle a situation/ don't have strategies for achieving what they want to achieve. So it is that frustration which the child has to pay in the name of education/ discipline(3).
- People are not skilled at interpreting the social situations, so out of confusion and irritation, they indulge in corporal punishment(3).
- Some can't control their emotions and as a consequence children become their victims of their anger/ rage/ even frustration(4).
- To some, it is pleasure as it relieves them(2).

Effects of corporal punishment

In our society, there are a set of social rules/ behavior which a child has to abide and if he/ she do not conform to the set social behavior, he/she is subjected to punishment. The punishment may vary from physical abuse to psychological abuse depending upon the adult.

As we all know every child is different so, every child responds differently to the menace of corporal punishment. It has also been seen that the uncontrolled anger of the adult, may result in injuries or even death of the child(4).

Effects of corporal punishment on children(5):

- It lowers the self-esteem of the child.
- It teaches them to be victims in future as well.
- It interferes with the learning process, intellectual, sensory and emotional development.
- It hampers the capacity to understand the relationship between behavior and its consequences.
- It promotes anegative view.
- It creates abarrier between child and adults, be it teach/ parent(6).
- It stimulates anger and desire to run away from home/ school.
- It teaches achild that violence is an accepted and the best way to tackle a problem.
- Such children experience difficulties with social integration.
- It teaches achild to comply with rules/ to infringe them.
- As is evident, many children suffer from accidental physical injuries.

Effects of corporal punishment on adults(2):

- It produces a feeling of anxiety and guilt.
- The use of corporal punishment increases the probability that parents will show aggressive behavior in the future with growing frequency and intensity and also in other contexts (4).
- Inhibits communication and damages the relationship between parents/ teachers and their children (5).

Children respect and admire adults whether parents/ teachers but these punishments may lead to anger and frustration which diminish the intimacy which the child has towards them and to cope up with the persistent abuse, the child indulges in self-destructive activities like alcohol abuse etc and even suicidal attempts (6),(7).

Chronic abuse of the child leads to abreachof the trust between the child and the parent/ teacher causing effects beyond physical/ mental trauma,

there is anerosion of the self-esteem, fear of closeness and ill-conceived attempts to avoid unpleasant reminders of child abuse(5).

News/ articles/facts

UNICEF statistics collected in 62 countries between 2005 and 2013 found that on average about four in five children aged 2-14 had experienced violent "discipline" (physical punishment and/or psychological aggression) at home.On average, 17% of children experienced severe physical punishment (being hit on the head, face or ears or hit hard and repeatedly) at home(8).

"A girl child who tried to commit suicide by jumping into a river as she couldn't tolerate the punishment(9)."

"Even parents asked teachers to be stern with them and put them into discipline by way of slapping children if they did not behave properly or do their work(10)."

"According to the Raghavancommittee,corporal punishment in schools was a contributory factor in thedevelopment of bullying tactics and ragging tendencies in students as per the observation of the supreme court of India(11)."

"In Medhanpalli village of Ranga Reddy district of Andhra Pradesh state in India, one teacher named Rose Merry poured molten wax from burning candle over groin region of a girl student of UKG and burned her skin. The teacher wanted the child to confess that she had stolen themoney of a fellow student. A case was registered against the teacher(12)."

"11year old girl of MCD School was punished for not doing the homework, was asked to stand in sun for >1hr (13). "

As is evidenced by the 'voices' profiled above corporal punishment does not mean physical violence on the child, but also verbal insults, humiliation, and loss of self-esteem. Self-perception of children gets altered if not wholly destroyed even before it emerges by such inhuman acts on tender minds.

Rights That Are Affected By Corporal Punishment(5):

- Right not to be subjected to torture or cruel, inhuman or degrading treatment or punishment
- Right to be protected from violence and abuse
- Right to development, including the right to the highest attainable standard of physical and mental health
- Right to dignity and bodily integrity.

How to prevent & control

Corporal punishment is exacerbated through social acceptance; as themajority of us believe smacking to be indispensable sometimes.For this reason, a nationwide social awareness campaign against corporal punish should be initiated, with objectives as follows(2),(14):

- Raising public awareness; about consequences.
- Encouraging positive and non-violent methods of child education and care in families and schools.
- Informing children about their rights.

It involves actions in schools, universities, different childhood associations and the media, and to provide training in different autonomous communities between parents and professionals involved in child care.

We should organize public debates, conferences and seminars on the Rights of the Child to make them aware (15).

Alternatives to corporal punishment are the best solution. The Legal Assistance Centre has also produced a movie on alternatives to corporal punishment **"A Betta Way"** which shows many other ways that children can be punished.(5) Here are four examples (15):

1. Explain the problem.
2. Make children take responsibility for their actions.

3. "Timeout": Sometimes children become overexcited and this can lead to bad behavior. It can be effective to take the child out of the room to calm down, sit quietly and think about what he or she has done wrong.

4. Take away privileges.

National commission for protection of child rights **(NCPCR)** has included slapping, beating with a scale, pinching, locking student alone in the room, making student sit like a chair or kneeling down and making a child run in the school as corporal punishment so as to give a direction to the teachers to forbid them from these practices. They have issued a set of guidelines on corporal punishment(16).

Parents should be particularly careful about the incidences inschool and should promote communication with their children to detect and avoid cases of corporal punishment and should not hesitate to reportcases of corporal punishment in schools to the school authorities so that repetition does not occur (17).

There is a growing appreciation for addressing the issue of corporal punishment as an act of violence(18). High Courts of Delhi (19), Chandigarh (20) as well as various other states, have banned corporal punishment for school children. There are many provisions through which the State can intervene on banning corporal punishment (16):

- The Juvenile Justice (Care and Protection) Act, 2006
- The Juvenile Justice (Care and Protection of Children) Rules, 2007
- The National Policy on Education (1986)
- The National Charter for Children (2003)
- National Plan of Action for Children 2005 (NPA)
- United Nations Convention on Rights of the Child, 1989 (*India acceded to this convention in 1992)*
- Constitution of India: *Article 3, 19, 21, 28, 37, 39, 40, 42*

Conclusion

Corporal punishment is just one of the wrong ways to discipline a child leading to erosion of the self-esteem, fear of closeness and ill-conceived attempts to avoid unpleasant reminders of child abuse.As theuse of corporal punishment is strongly rooted in our society and is passed on through generations, this doesn't mean that corporal punishment is justified. So, putting an end to corporal punishment is our ethical duty.

There are rules and judgments by the courts which admonish corporal punishment but still the corporal punishment is being practiced in various parts of the country; reason being the lack of awareness about the laws and fallouts of corporal punishment on the future life of children.

Child discipline is very important so, alternatives to corporal punishment should be chosen to educate/ discipline them.

"Your hands should nurture not punish them."

References

1. United Nations Committee on the Rights of the Child, U.N. Doc. CRC/C/GC/8. 2 March 2007, Editor, 42nd Sess., U.N.Doc. CRC/C/GC/8. General comment No. 8 (2006): The right of the child to protection from corporal punishment and/ cruel or degrading forms of punishment (articles 1, 28(2), and 37, inter alia. 2007.
2. Educate, Don't punish: Awareness campaign against corporal punishment of children in families. First session. Save the Children. UNICEF, CEAPA, CONCAPA; 1999 Oct.
3. Lansford JE, Deater-Deckard K, Bornstein MH, Putnick DL, Bradley RH. Attitudes justifying domestic violence predict endorsement of corporal punishment and physical and psychological aggression towards children: A study in 25 low-and middle-income countries. J Pediatr. 2014;164(5):1208–13.
4. Taylor CA, Lee SJ, Guterman NB, Rice JC. Use of spanking for 3-year-old children and associated intimate partner aggression or violence. Pediatrics. 2010;peds – 2010.
5. Basic facts about corporal punishment. Fact sheet Gender Research & Advocacy Project. Legal Assistance Center, Windhoek, Namibi;
6. Corporal punishment to children: review of research on its impact and association, working paper. London: Global initiative to end all corporal punishment of children.; 2015.
7. Oliver M. Spanking: Questions & Answers about disciplinary violence. 2005;
8. Unicef, others. Hidden in plain sight: A statistical analysis of violence against children. 2014 [cited 2016 Dec 17]; Available from: http://www.chimat.org.uk/resource/item.aspx?RID=212165
9. Amar Ujala 5(122). 2007;1.

10. Singh R. Disciplining the child. The Tribune 127(224). late city ed. 2007;14.
11. File criminal cases in ragging incidents: SC,. The Tribune 127(135). late city ed. 2007;1.
12. Press Trust of India. Be-rahamshikshaknegarm mom semassomchhatarkijanghjalai. Dainik Jagran 2(45). 2009;8.
13. HT Correspondent. School girl sent to stand in sun, critical. Hindustan Times. 2009;1.
14. Jean D, Lormand D, Waxweiler R. Developing policies to prevent injuries and violence: guidelines for policy-makers and planners. World Health Organization; 2006.
15. Gorea A, Gorea L, Gorea RK, Arora A. Holistic approach to prevent injuries and corporal punishments in schools. Egypt J Forensic Sci. 2011;1(1):25–9.
16. Protection of Children against Corporal Punishment In Schools and Institutions. National Commission for the Protection of child rights; 2008.
17. Gorea RK. Corporal punishment in schools: Global status and remedial measures. Int J Ethics Trauma Vict. 2015;1(2):6–8.
18. Indiana corporal punishment in public schools laws [Internet]. Available from: FindLaw.htm
19. Parents forum for meaningful education and another vs. Union of India and another. 1998.
20. The Tribune 120(33). City ed. 2000;1.

Rupture of mature cystic teratoma induced by a car accident

Dr. A. Morgan, MD, PhD. Department of Trauma, St. George Hospital, Sydney, Australia.

Citation:Morgan A. Rupture of mature cystic teratoma induced by a car accident. *Int J Eth Trauma Victimology 2016*; 2(2):26-29. doi: 10.18099/ijetv.v2i02.6858

Article history

Received: August 23, 2016
Received in revised form: Nov 10, 2016
Accepted: Nov 18, 2016
Available online: Dec 28, 2016

Corresponding author

Dr. A. Morgan, Department of Trauma, St. George Hospital, Sydney, Australia

Phone:++966582346622
Email: anatoly90@hotmail.com

Abstract

Benign cystic tumors can originate from the retroperitoneum and are known to develop in adult males and females asymptomatically. Radiological diagnosis of teratomas in the retroperitoneal region is difficult and often confused with myelolipoma or other lipomatous tumors. This case report describes the incidental finding of mature cystic teratoma of the retroperitoneal region, which ruptured post motor vehicle accident (MVA) in 31years, old female patient. The patient present to the emergency department 24 hours post-accident with symptoms and signs of peritoneal inflammation. As a result of the seat belt injury, the cystic teratoma of the left retroperitoneum had ruptured. Due to anatomical location, the cyst was only partially removed. This case report has raised multiple clinical dilemmas and is the first of its kind in trauma patient management of mature cystic teratoma.

Keywords: Cystic teratoma, traumatic rupture, abdominal trauma, seat belt injury, aseptic peritonitis, diagnostic laparoscopy.

© IJETV. All rights reserved

Introduction

Benign cystic teratomas, as well as other germs cell tumors, can originate not only from gonads but also from the retroperitoneum and are known to develop in adult males and females asymptomatically. Only a few cases of teratomas in the vicinity of the retroperitoneal space have been reported around the world, especially in adults (1),(2),(3),(4),(5),(6),(7),(8). Teratoma is a germ-cell tumor, which contains well-differentiated tissues from embryonic layers. As a result of this, they are encountered commonly in the gonads. Our report describes a mature cystic teratoma in the retroperitoneal region in a patient, which was incidentally discovered post-MVA trauma.

Case Report

A 31 year old female presented to emergency department (ED) post MVA with a minor laceration to her left forehead. She was a rear-seat passenger when the car was T-boned by another vehicle traveling at speed of 70 km/hr. The other passengers remained unharmed. When she presented, her only medical history was a large ovarian cyst, which had been removed in her 20's. She also suffered intermittently from upper abdominal pain since the age of 10, which was not investigated previously and did not take any regular medications. On initial examination she was hemodynamically stable, Glasgow coma scale (GCS) was 15 and the computer tomography (CT) scan of head and neck was normal. Focused assessment with sonography for trauma (FAST) scan was negative. Tertiary survey did not reveal any other injuries. Her forehead laceration was managed and the patient was discharged home.

However, 12 hours later the patient represented with upper abdominal pain. Examination showed a body temperature of 38.3^{0}C, heart rate (HR) of 94, her blood pressure (BP) was 115/67 and blood oxygen saturation of 100% on room air. The abdomen on examination was soft, distended and tender in the left upper quadrant. FAST scan revealed free intra-abdominal fluid.

Fig 1A: Axial abdominal CT with contrast showing large retroperitoneal cysticlesion with area of calcification.

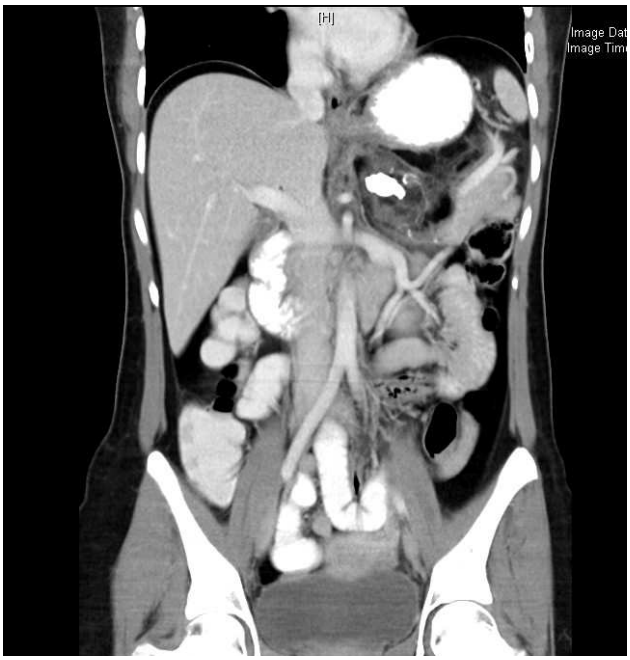

Fig. 1B: Representative coronial view showing retroperitoneal calcificationwith surrounding high density cystic content.

Provisional diagnosis was made as seat belt bowel injury or splenic injury at that stage. CT scan of abdomen performed to confirm initial diagnosis showed a large mixed density mass 10 x 9 cm in retroperitoneum. The finding location was focused around left adrenal gland and characterized by fat density with calcified rim and central coarse calcification. It also demonstrated soft tissue stranding and free fluid in the abdominal cavity with no free intra-abdominal gas. The liver, spleen, and kidneys were of normal appearance with no evidence of injury. In conclusion, a diagnosis of myelolipoma with post-traumatic hemorrhage was suggested (Fig 1A and B).

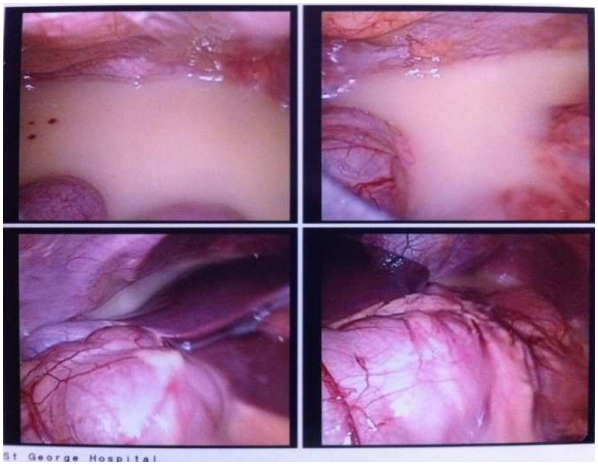

Fig. 2: Laparoscopic view of the patient's peritoneal cavity after ruptured cystic teratoma.

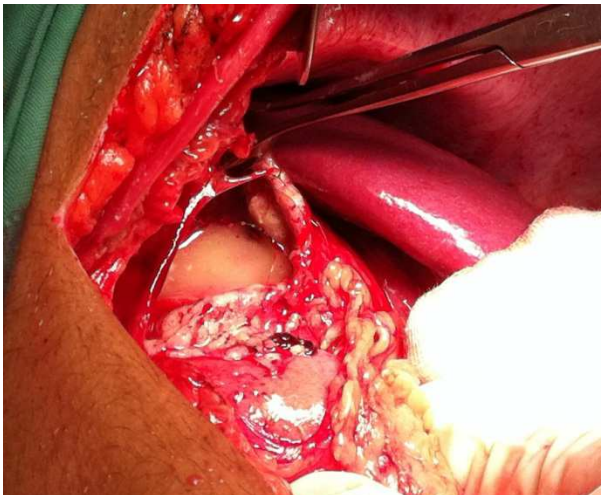

Fig. 3: Intra-operative view of the ruptured retroperitoneal cyst.

Clinically, the patient's condition was deteriorating rapidly with developing symptoms and signs of sepsis. Her full blood count (FBC) included white cells count (WCC) of 14, hemoglobin (Hb) of 144, hematocrit (Ht) of 0.42 and lactate 2.1, which suggested acute inflammatory reaction rather than intra-abdominal bleeding. Based on this a decision

for the emergency surgical procedure was made and the patient was taken to the operating theater for diagnostic laparoscopy. The finding at laparoscopy revealed a large amount of pale, not purulent fluid with fatty inclusions (Fig.2). The procedure was converted to laparotomy with approximately 1.5 L of pus like odor free fluid aspirated. No injuries to the liver, spleen, small and large bowel including right retroperitoneal space were identified. The fluid source was the left side retroperitoneal cyst which was located between the stomach, spleen and left kidney (Fig.3). The cyst contained a large volume of yellow pale mucous and packed hair (Fig.4). The cyst was intimately attached to the splenic hilum, greater curvature of stomach anteriorly and upper renal pole. During removal of the cyst preservation of the spleen was not possible, as the splenic vessels were adherent to the cyst wall. Also, the cyst wall contained the entire left adrenal gland. It was necessary to perform a splenectomy and left adrenalectomy. About 80% of the cyst was removed as the remainder of the wall was intimately adjacent to the left renal vein. The abdominal cavity was flushed with antiseptic solution and normal saline following by placement of a large Blake drain. The patient recovery was unremarkable and she was discharged 10 days post operation.

Fig. 4: Content of the ruptured cystic teratoma with hair and adipose material.

The sample of the cyst with adjacent structures was sent for histopathology analysis, which showed a mature cystic teratoma lined by skin with adnexal elements (fat and hair) including minor salivary gland tissue. The capsule of the cyst showed extensive fibrous tissue with dystrophic calcification. A portion of the adrenal gland was also intimately associated with the cyst capsule. There were no immature elements and no evidence of malignancy.

Discussion

Our experience with the mature cystic teratoma was due to a female patient presented post-MVA, causing rupture of the cyst as consequence of seat belt injury from the impact.

The anatomical location of the teratoma was in the left retroperitoneal region involving left adrenal gland, which has a very rare presentation. What makes this case also unique is that the patient was presenting to the hospital emergency with symptoms of peritonism similar to delayed presentation of a ruptured viscus or intra-abdominal bleeding. It was unexpected to find a large cystic teratoma in view of not conclusive preoperative radiological findings.

During the management of this case, surgeons faced several issues. Firstly, difficult to distinguish teratoma from other lipomatous tumors of retroperitoneal space, such as myelolipoma or angiolipoma (2),(9),(10) by radiological findings and diagnosis of bleeding myelolipoma suggested by CT scan was misleading. Secondly, the anatomical location of the cyst with intimately adjusted wall to the major blood vessels and vital organs. Thus, presenting a surgical technical challenge to remove the cyst without complications, keeping in mind the possibility of the malignancy. There are very few published cases of retroperitoneal teratoma in the English literature and all have demonstrated difficulties in the radiological diagnosis of the condition and management.

Also, the management issue, in this case, was that cystic teratoma has a potential risk of malignancy. Our patient had a “benign” grade 0 teratoma, however, malignant endodermal sinus tumor has been reported previously (11),(12). This patient had incomplete removal of her cyst due to anatomy related technical difficulties, which leads to our tertiary issue of long-termfollow-up (13),(14). It has been reported, that risk factors for malignant transformation of mature cystic teratoma may include older age with postmenopausal status, large tumor mass and elevated CA-125 level (15). Adequate follow-up requires close observation, involving repeated physical examination, scanning (ultrasound, MRI, or CT), and measurement of AFP, βhCG, and CA-125. We decided the best course of action in this instance was to work in conjunction with the oncology team.

Conclusion

This case report describes a rather unusual presentation of post-traumatic aseptic peritonitis caused by the rupture of large cystic teratoma which was initially misleading for clinicians, simulating intra-abdominal bleeding or traumatic perforated viscus. The absence of shock features with negative FAST was urging to perform diagnostic laparoscopy, which confirmed the present of the free fluid of cystic nature. Although this case is rare, it highlights the importance for surgeons to be aware of possible scenarios and enhancing the role of diagnostic laparoscopy for pathology clarification and surgical decision making. We believe this case report is the first to raise the issue of management of incomplete removal of the mature cystic teratoma and will contribute to detection and management of future cases. Another point of note is that the mature cystic teratoma should be considered as a differential diagnosis of adrenal lipomatous tumors, not only in children but also in adults.

References

1. Lam K, Lo C. Teratoma in the region of adrenal gland: a unique entity masquerading as lipomatous adrenal tumor. Surgery. 1999;126:90–4.
2. Bedri S, Erfanian K, Schwaitzberg S, Tischler A. Mature cystic teratoma involving adrenal gland. Endocr Pathol. 2002;13(1):59–64.
3. Polo J, Villarejo P, Molina M, Yuste P, Menéndez J, Babé J, et al. Giant mature cystic teratoma of the adrenal region. AJR Am J Roentgenol. 2004;183:3.
4. Sato F, Mimata H, Mori K. Primary retroperitoneal mature cystic teratoma presenting as an adrenal tumor in an adult. Int J Urol. 2010;17(9):817.
5. Oguzkurt P, Ince E, Temiz A, Demir S, Akabolat F, Hicsonmez A. Prenatal diagnosis of a mass in the adrenal region that proved to be a teratoma. J Pediatr Hematol Oncol. 2009;31(5):350–1.
6. Hui J, Luk W, Siu C, Chan J. Teratoma in the Region of an Adrenal Gland in a 77-year-old Man. J HK Coll Radiol. 2004;7:206–9.
7. Shrestha M, Lalchan S. Adrenal gland teratoma in a 40-year-old woman. Nepal Med Coll J. 2010;12(3):201–2.
8. Rais-Bahrami S, Varkarakis I, Lujan G, Jarrett T. Primary retroperitoneal teratoma presenting as an adrenal tumor in an adult. Urology. 2007;69(1):185.
9. Khong P, Lam K, Ooi C, Liu M, Metreweli C. Mature teratomas of the adrenal gland; imaging features. Abdom Imaging. 2002;27(3):347–50.
10. Cranston P, McPherson S. Para-adrenal teratoma: CT presentation. South Med J. 1989;82(4):518–9.
11. Ohno Y, Kanematsu T. An endodermal sinus tumor arising from a mature cystic teratoma in the retroperitoneum in a child: is a mature teratoma a premalignant condition? Hum Pathol. 1998;29(10):1167–9.
12. Utsuki S, Oka H, Sagiuchi T, Shimizu S, Suzuki S, Fujii K. Malignant transformation of intracranial mature teratoma to yolk sac tumor after late relapse. Case report. J Neurosurg. 2007;106(6):1067–9.
13. Mann J, Gray E, Thornton C, Raafat F, Robinson K, Collins G, et al. Mature and immature extracranial teratomas in children: the UK Children's Cancer Study Group Experience. J Clin Oncol. 2008;26(21):3590–7.
14. Lo Curto M, D'Angelo P, Cecchetto G, Klersy C, Dall'Igna P, Federico A, et al. Mature and immature teratomas: results of the first paediatric Italian study. Pediatr Surg Int. 2007;23(4):315–22.
15. Park C, Jung M, JI Y. Risk factors for malignant transformation of mature cystic teratoma. Obstet Gynecol Sci. 2015;58(6):475–80.

It should not hurt to be a child:ACase Report

Dr. Apoorva Gupta, Junior resident, Department of Oral Medicine & Radiology, Teerthanker Mahaveer Dental College & Research Center, Moradabad, UP, India.
Dr.V.Naveen Shankar, Professor, Department of Oral Medicine & Radiology, Teerthanker Mahaveer Dental College & Research Center, Moradabad, UP, India.
Dr. SV Ravindra, Reader, Department of Oral Medicine & Radiology, Teerthanker Mahaveer Dental College & Research Center, Moradabad, UP, India.

Citation:Gupta A, Shankar VN, Ravindra SV. Educate: Don't punish. *Int J Eth Trauma Victimology 2016*; 2(2):30-33. doi: 10.18099/ijetv.v2i02.6859

Article history

Received: August30, 2016
Received in revised form: Nov 11, 2016
Accepted: Nov27, 2016
Available online: Dec 28, 2016

Corresponding author

Dr. Apoorva Gupta, Junior resident, Department of Oral Medicine & Radiology, Teerthanker Mahaveer Dental College & Research Center, Moradabad, UP, India

Phone:+918979917191
Email: gupta_apoorva@live.com

Abstract
As custodians of children's hopes and aspirations, we must accept the responsibility for creating an environment that will help children thrive. Child abuse is a major public health problem all over the world. It can be in the form of physical, sexual, emotional or just neglect in providing for the child's needs. These factors can leave the child with serious, long-lasting psychological damage. Violence against children, including corporal punishment, is a violation of the rights of the child. It conflicts with the child's human dignity and the right of the child to physical integrity.As most of the abuse injuries occur in the head and neck, dentists can easily diagnose them and as health care professionals, it is our duty to detect such abuses at an early stage to prevent further harm to the child and counseling of the abusive caretaker. The management of child abuse can be complicated, and often require a multidisciplinary approach, encompass professionals who will identify the cause of the abuse or neglect, treatment of the immediate problems and referral of the child to the relevant child protection authority for action. The involvement of dentists in child protection teams would be beneficial in two ways, dentists would become aware of their role and would assist in the training of physicians and other professionals.

Keywords: Corporal punishment, physical punishment, schools

© IJETV. All rights reserved

Introduction

Human beings are one of the beautiful creatures of God and above all understanding, a child is the most important thing one should learn. It is very helpful in becoming effective in guiding and nurturing the child as they grow and mature. One need to bear in mind that the child has a unique personality trait that remains constant throughout his life (1).So, one should not hurt a child. Corporal punishment is forced pain intended to change a person's behavior or to punish them which may cause physical and mental injuries. Discipline is the training that corrects molds or perfects the mental facilities or moral character. Abuse means the improper or excessive use or treatment, mostly physical maltreatment (2).

Forms of child maltreatment

Child maltreatment may occur either within or outside the family. The proportion of interfamilial to extrafamilial cases varies with the type of abuse as well as the gender and age of the child. Each of the following conditions may exist as separate or concurrent diagnoses (3).

Physical abuse: It is most common inflicted by caregiver or family member. The most common manifestations include bruises, burns, fractures, head trauma, and abdominal injuries (4).

Sexual abuse: Sexual abuse is defined as the engaging of dependent, developmentally immature children in sexual activities that they do not fully comprehend and to which they cannot give consent or activities that violate the laws and taboos of a society. It includes all forms of incest, sexual assault or rape, and pedophilia (5).

Emotional abuse: Emotional or psychological abuse has been defined as the rejection, ignoring, criticizing, isolation, or terrorizing of children, all of which have the effect of eroding their self-esteem. The most common form is verbal abuse or denigration (6).

Physical neglect: It is the failure to provide the necessary food, clothing, and shelter and a safe environment in which children can grow and develop (5).

Emotional neglect: It is the absence of normal parent–child attachment and a subsequent inability to recognize and respond to an infant‘s or child‘s needs. A common manifestation of emotional neglect in infancy is a nutritional (nonorganic) failure to thrive.

Medical care neglect: It is failure to provide the needed treatment to infants or children with life-threatening illness or other serious or chronic medical conditions (6).

Munchausen syndrome by Proxy: It is a relatively unusual disorder in which a caregiver, usually the mother, either stimulates or creates the symptoms or signs of illness in a child (7).

Corporal punishment may lead to lowered self-esteem in children, teaches them to be victims throughout their lives, interferes in the learning process, they feel lonely and abandoned, develops a negative attitude in them, stimulates anger and may even cause accidental physical injuries in the children (8).

Detection of child abuse in the Dental Office

Parents must pay attention to what is happening in schools and should maintain a good communication with children for early detection of corporal punishment (9).When a child presents for examination, particularly if there is an injury involved, the history may alert the dental team to the possibility of child abuse. Indeed, the history may be the single most important source of information (10).

General Physical findings: The child’s nutritional status is poor and the growth is found subnormal. There are many of the extra oral injuries seen including bruises or abrasions, cigarette burns or friction burns and bite marks, bald patches, injuries to extremities or around the mouth (3).

Findings on Dental examination: Examination of dental injuries includes thorough visual observation, radiographic studies, manipulation of the jaws, pulp vitality tests, and percussion.Both oral and facial injuries of child abuse may occur alone or in conjunction with injuries to other parts of the body. The oral lesions associated with child abuse are usually bruises, lacerations, abrasions, or fractures. The scars, particularly on the lips, are evidence of previous trauma and should alert the investigator to the possibility of child abuse. Tears of the frenula, particularly the labial frenulum, are frequently seen in child abuse cases. These injuries may result from blunt force trauma. Blunt force trauma to the lower face may also cause the mucosal lining of the inner surface of the lip to be torn away from the gingiva(11). Severe trauma to the lower face may loosen teeth, completely displace them from their alveolar sockets, and/or cause dental fractures (12). It is not uncommon to find contusions, lacerations, burns, or scars on the lips of abused children. Bruises to the lip may result from forced feeding. Burns on the lip, as well as burns on the face or tongue, may be signs of physical punishment (11).The tongue of an abused child may exhibit abnormal anatomy or function due to scarring. Trauma to the mouth may also cause ulceration of the palate or uvula(13). Fractures of the maxilla, mandible, and other cranial bones may be found in cases of child abuse. If the radiologic study shows signs of old as well as new

fractures, a pattern of repeated trauma has been found and needs to be investigated with reference to possible child abuse. A child with rampant, untreated dental decay and poor oral hygiene are suffering from significant neglect. The consequences may be apain, infection, and a threat to the child's general health and well-being (3). Blain reports that a preliminary study supports the high correlation between dental neglect and CAN (child abuse and neglect) (14).

Case Report

A five-year-old male patient came to the department of Oral Medicine and Radiology, TeerthankerMahaveer Dental College and Research Center with a chief complaint of pain on upper right back tooth region since 4-5 months. On taking a detailed history, it was revealed that the child's teacher had a habit of pinching his gingiva in that region. He does this whenever he feels lonely and abandoned and no one loves or cares for him at home. When the mother was asked a series of questions, it was noted that she belongs to a very poor family and is unable to take proper care of her children. She has to go out and work and earn the daily income to run the family with six kids. On clinical examination, there was a denuded area seen on the gingival surface in relation to 54, 55 region. The parent was informed about the situation and was educated to take proper care of the health and needs of her child.

Fig. 1: Face of the victim child

Fig. 2: Gingiva showing denuded area

Discussion

Becker et al found that in their series of facial injuries in abused children, 66% of the injuries were contusions and ecchymosis, 28% were abrasions and lacerations, 3% burned, 2% were fractured and 1% bit (15).Kessler and Hyden pointed out that after the injury occurs, the area is usually tender and swollen, but the bruise may not be visible as contusion or ecchymosis for 24 to 72 hours. A reddish blue or purple color may be visible immediately or within the first 5 days. This initial color may change to green in 5 to 7 days, then to yellow in 7 to 10 days, then to brown in 10 to 14+ days, before clearing in 2-4 weeks (10).The present is a case of self-inflicted injury to the gingiva by a five-year-old child due to the lack of emotional support. Rajiv Subbaiah et al reported a case series of self-inflicted injuries of gingiva including fingernail trauma, acid burn, toothbrush irritation, chemical burn, toothbrush abrasion in different children (16).Arfin et al reported a case of self-inflicted palatal soft tissue injury in a 7-year-old child because of negligence and ill-treatment in school (17).

Conclusion

The child needs emotional and supportive care, the lack of which may ruin his life. So everyone, especially the parents of the child must take proper care of their children and give them support. They should educate them, not harm them.

References

1. Robert M. A quick guide to understanding your child. 1999;

2. Position paper of the Society for adolescent medicine. Corporal punishment in schools. J Adolesc Health. 2003;32:385–93.
3. Somani R, Kushwah V, Kumar D, Khaira J. Child abuse and its detection in the Dental Office. J Indian Acad Forensic Med [Internet]. 2011 [cited 2016 Dec 17];33(4). Available from: http://imsear.li.mahidol.ac.th/handle/123456789/143423
4. American Academy of Pediatrics. Distinguishing sudden infant death syndrome from child abuse fatalities. Pediatrics. 2001;107(2):437–41.
5. American Academy of Pediatrics: Diagnostic imaging of children abuse. Pediatrics. 2000;105(6):1345.
6. Pediatrics AA of, others. Visual diagnosis of child abuse on CD-ROM. na; 2003.
7. Pediatrics AA of, others. Visual Diagnosis of Child Sexual Abuse. Slide Set Atlas] American Academy of Pediatrics; 1998.
8. Naker D, Sekitoleko D. Positive discipline: creating a good school without corporal punishment. Kampala Rais Voices. 2009;
9. Gorea RK. Corporal punishment in schools: Global status and remedial measures. Int J Ethics Trauma Vict. 2015;1(2):6–8.
10. Kessler DB, Hyden P. Physical, sexual, and emotional abuse of children [Internet]. CIBA-GEIGY Corporation; 1991 [cited 2016 Dec 17]. Available from: https://www.ncjrs.gov/App/Publications/abstract.aspx?ID=137816
11. McNeese MC, Hebeler JR. The abused child: a clinical approach to identification and management. In: Clin Symp [Internet]. 1977 [cited 2016 Dec 17]. p. 1–36. Available from: https://www.ncjrs.gov/App/Publications/abstract.aspx?ID=58371
12. Andreasen JO. Traumatic injuries of the teeth. WB Saunders Company; 1981.
13. Blain S. Child abuse, Pediatric Dentistry; Scientific Foundations and ClinicalPractice, Stewart, R. E. et al. St. Louis: C. V. Mosby; 1981.
14. Blain SM. Abuse and neglect as a component of pediatric treatment planning. J Calif Dent Assoc. 1991;19(9):16–24.
15. Becker DB, Needleman HL, Kotelchuck M. Child abuse and dentistry: orofacial trauma and its recognition by dentists. J Am Dent Assoc. 1978;97(1):24–8.
16. Subbaiah R, Thomas B, Maithreyi VP. Self-inflicted traumatic injuries of the gingiva-A case series. J Int Oral Health. 2010;2(2):43–9.
17. Arfin S, Tasneem S, Khan SY, Jindal MK. Self-Inflicted Palatal Soft Tissue Injury: A Case Report. 2014 [cited 2016 Dec 17];2(10). Available from: http://www.usa-journals.com/wp-content/uploads/2014/09/Arfin_Vol210.pdf

Occipitalization and its clinical relevance: A case report

Dr. Bindu Aggarwal, Professor and Head, Department of Anatomy, Luxmi Bai Dental College, Patiala, Punjab, India.
Dr. Rakesh K Gorea, Faculty member, College of Medicine, Prince Sattam bin Abdulaziz University, al Kharj, Kingdom of Saudi Arabia.
Abhinav Gorea, Edith Cowan University, Australia.
Arshdeep Gorea, Edith Cowan University, Australia.

Citation:Aggarwal B, Gorea RK, Gorea A, Gorea A. Occipitalization and its clinical relevance: A case report.*Int J Eth Trauma Victimology 2016*; 2(2):34-37. doi: 10.18099/ijetv.v2i02.6860

Article history

Received: September 25, 2016
Received in revised form: Dec 1, 2016
Accepted: Dec 18, 2016
Available online: Dec 28, 2016

Corresponding author

Dr. Bindu Aggarwal
Professor and Head, Department of Anatomy, Luxmi Bai Dental College, Patiala, Punjab, India.

Phone:+919855126677
Email: drbindusanjay@gmail.com

Abstract
Occipitalization of the atlas or atlanto-occipital fusion is one of the osseous anomalies of the craniovertebral junction. This fusion may be partial or complete and can be due to failure in segmentation and separation of the most caudal occipital sclerotome and the first cervical sclerotome.We present a case report of complete occipitalization of the atlas which was observed during undergraduate teaching at Luxmi Bai Dental College, Patiala. Such an anomaly is of interest to anatomists, physicians, radiologists &neurologists as it can cause a variety of neurological symptoms. Occipitalization can cause sudden death and an antemortem record of such an anomaly can help in identification of the deceased. Hence, occipitalization can be of interest to the forensic investigators in establishing the identity of the deceased.

Keywords: Occipitalization, atlanto-occipital fusion, sudden death, identification.

© IJETV. All rights reserved

Introduction

Occipitalization or fusion of atlas with occipital bone is a rare congenital malformation at the craniovertebral junction known as occipitocervical synostosis, occipitalization of the atlas, or atlanto-occipital fusion(1). During the fourth week of intrauterine life, the atlas partially or totally fuses with the occipital bone due to failure in segmentation and separation of the most caudal occipital sclerotome and the first cervical sclerotome(2). Such patients usually develop neurological symptoms after thesecond decade of life(3). Occipitalization of atlas may be partial or complete(4). Tubbs(5) stated that occipitocervical synostosis is usuallycongenital, but in rare cases, it may be a result of osteomyelitis, arthritis, syphilis or tuberculosis. Occipitalization of atlas can produce a wide range of neurological signs and symptoms varying from a transitory headache to full-blown neurological syndrome(6). This can even lead to sudden death(7). The knowledge of such an anomaly is important for anatomists, radiologists, orthopedists, neurosurgeons & forensic experts.

Case Report

During the osteology demonstration class for undergraduate students, a case of occipitalization of theatlas was observed (Fig 1). The skull of unknown origin and gender belonged to the archives of Luxmi Bai Dental College, Patiala. The following observations were made and the measurements were taken with Verniercalipers:

- The anterior arch was completely fused with the occipital bone, near the margins of theforamen magnum (Fig 2).
- The posterior arch was almost completely fused with the occipital bone, near the margins of theforamen magnum, leaving a small gap at the level of posterior tubercle of theatlas (Fig 3). This gap measured 8.5mm transversely & 4.5mm vertically.

- The lateral masses were fused with the occipital condyles completely.
- The transverse processes were fused to the occipital bone.
- The foramen transversarium were normal. The anteroposterior& transverse diameters of the right foramen transversarium were 6.45mmx6.68mm. The anteroposterior& transverse diameters of the left foramen transversarium were 6.45mmx6.64mm.
- The foramen magnum appeared normal. The dimensions of the foramen magnum were 30mm transversely and 32 mm anteroposterior.

Discussion

The bony anomalies at craniocervical junction have been studied previously by various authors(8), (9), (10),(11).Occipitalization of theatlas is a congenital synostosis of the atlas to the occiput, which is a result of thefailure of segmentation and separation of the most caudal occipital sclerotome and the first cervical sclerotome during the first few weeks of fetal life(12). There may be varying degrees of bony fusion between atlas and occiput; partial or complete(13). The complete fusion of the atlas is more common than the incomplete(14). In the present study, one skull was observed with complete occipitalization. Similar findings were observed in two skulls by Saini(15)and in three skulls by Walia(16).

Foramen magnum normally measures about 30mm transversely and 35mm anteroposteriorly(17).Atlantooccipital fusion can reduce the foramen magnum dimension leading to neurological complications due to compression of thespinal cord, vertebral arteries, and first cervical nerve(18),(19),(20),(21). In the present study, dimensions the of the foramen magnum were 30mm transversely and 32 mm anteroposteriorly. In a study by Soni(22), the same diameters were reduced to 25mm x 19mm due to the fusion. In another study by Skrzat (23), the circumference of the foramen magnum was also diminished due to thefusion of atlas to the occipital bone.

According to some studies(24),(25),(26), atlantoaxial dislocation occurs in about 60% of patients with the anomaly of occipitalization of theatlas and can

Fig. 1: Fusion of atlas & occipital bone.

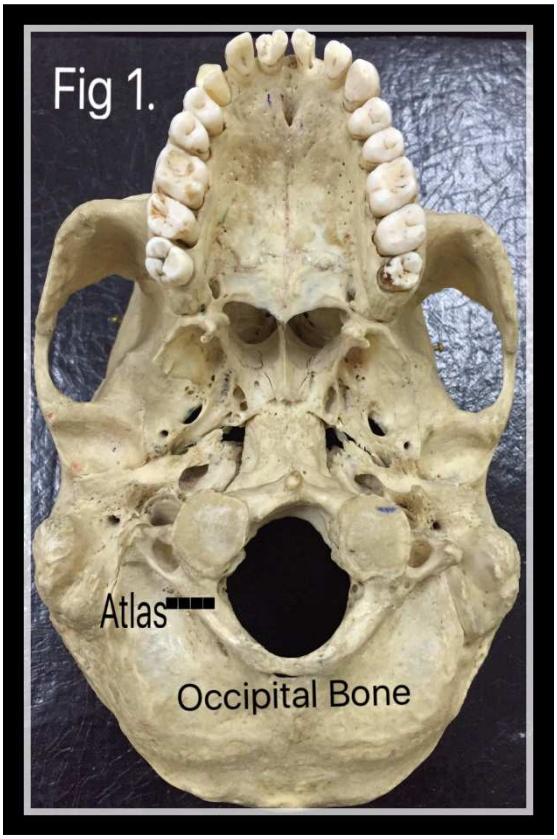

Fig. 2: Anterior arch of Atlas fused completely with occipital bone.

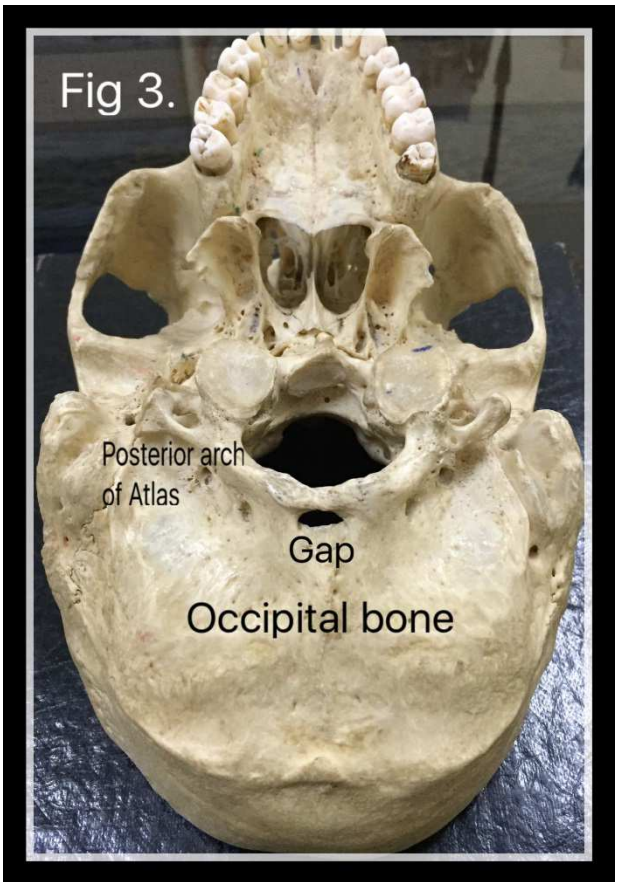

Fig. 3: Posterior arch of Atlas fused almost completely with occipital bone, leaving a small gap at the level of posterior tubercle of the atlas.

neurological symptoms. The neurological symptoms vary from a transitory headache to full-blown neurological syndrome. Skeletal abnormalities at the craniocervical junction may result in sudden death(7),(16),(27),(28),(29).

The skeleton which is the most durable part of the body(30), furnishes information to the Forensic investigators who are primarily concerned with personal identification. Examination of the skeletal remains in comparison with the antemortem details like dental charts, medical records and x-rays of the suspected victim provide important means of comparative identification(31),(32),(33).

Conclusion

From the present study, we can conclude that occipitalization of the atlas is an anomaly where the atlas is fused with the occipital bone. Such a fusion can lead to narrowing of the foramen magnum. These anomalies are also more likely to have cause atlantoaxial dislocations. These conditions can cause neurological symptoms ranging from a headache to full-blown neurological syndrome to sudden death. The neurological complications can occur due to compression of thespinal cord, vertebral arteries, and first cervical nerve. The antemortem records of such an anomaly can help in the identification of the deceased. This study is therefore of interest to anatomists, radiologists, neurologists, orthopedists & forensic investigators.

References

1. Mudaliar R, Shetty S, Nanjundaiah K, Kumar J. An osteological study of occipitocervical synostosis: its embryological and clinical significance. J Clin Diagn Res. 2013;7:1835–7.
2. Guebert G, Yochum T, Rowe L. Congenital anomalies and normal skeletal variants. In: Yochum TR, Rowe LJ, editors. Essentials of skeletal radiology. Baltimore: Williams and Wilkins; 1987.
3. Kayhan B, Ilhan P, Erturk M, Sengul G. Occipitocervical synostosis: case report. Int J Exp Clin Anat. 2015;9(2):104–7.
4. Pang D, Thompson D. Embryology and bony malformations of the craniovertebral junction. Childs Nerv Syst. 2011;27:523–64.
5. Tubbs R, Salter E, Oakes W. The intracranial entrance of the atlantal segment of the vertebral artery in crania with occipitalization of the atlas. J Neurosurg Spine. 2006;4:319–22.
6. Campos D, Silva T, Ellwanger J, Goerck M, Kipper J, Piazza J, et al. Atlanto-occipital fusion and its neurological complications: a case report. J Morphol Sci. 2012;29(2):111–3.
7. Vakili S, Aguilar J, Muller J. Sudden unexpected death associated with atlanto-occipital fusion. Am J Forensic Med Pathol. 1985;6(1):39–43.
8. Rao P, Mbajiorgu E, Levy L. Bony anomalies of the craniocervical junction. Cent Afr J Med. 2002;48(1-2):17–23.
9. Erbengi A, Oge H. Congenital malformations of the craniovertebral junction: classification and surgical treatment. Acta Neurochir. 1994;127(3-4):180–5.
10. Grob D. Fusion in craniocervical malformation. Eur Spine J. 2009;18(8):1241–2.
11. Abumi K, Avadhani A, Manu A, Rajasekaran S. Occipitocervical fusion. Eur Spine J. 2010;19(2):355–6.
12. Hayes M, Parker G, Ell J, Sillence D. Basilar impression complicating osteogenesis imperfacta type IV: the clinical and neuroradiological findings in four cases. J Neurol Neurosurg Psychiatry. 1999;66:357–64.

13. Ranade A, Rai R, Prabhu L, Kumaran M, Pai M. Atlas assimilation: a case report. Neuroanatomy. 2007;6:32–3.
14. Kalla A, Khanna S, Singh I, Sharma S, Schnobel R, Vogel F. A genetic and anthropological study of atlanto-occipital fusion. Hum Genet. 1989;81:105–12.
15. Saini V, Singh R, Bandopadhyay M, Tripathi S, Shamal S. Occipitalization of the atlas: its occurrence and embryological basis. Int J Anat Var. 2009;2(65-8).
16. Walia S, Modi B, Puri N, Patnaik V. Occipitalization of Atlas. Int J Anat Res. 2014;2(4):781–4.
17. Muralidhar P, Magi M, Nanjundappa B, Havaldar P, Gogi P, Hussain S. Morphometric analysis of foramen magnum. Int J Anat Res. 2014;2(1):249–55.
18. Hussain S, Mavishetter G, Thomas S, Prasanna L, Muralidhar P. Occipitalization of Atlas: A case report. J Biomed Sci Res. 2010;2(2):73–5.
19. Bose A, Shrivastava S. Partial occipitalization of atlas. Int J Anat Var. 2013;6:81–4.
20. Greenberg A. Atlanto - axial Dislocations. Brain. 1968;91:655–84.
21. Hemamalini. Atlanto-occipital fusion and other variations at the base of the skull: a case report. Int J Anat Var. 2014;7:80–2.
22. Soni P, Sharma V, Sengupta J. Cervical vertebrae anomalies–incidental findings on lateral cephalograms. Angle Orthod. 2008;78:176–80.
23. Skrzat J, Mroz I, Jaworek J, Walocha J. A case of occipitalization in the human skull. Folia Morphol. 2010;69(3):134–7.
24. McRae D, Barnum A. Occipitalization of atlas. AJR. 1953;70:23–46.
25. Sinh G. Congenital atlantoaxial dislocation. Neurosurg Rev. 1983;6:211–20.
26. Jain V, Takayasu M, Singh S, Chharbra D, Sugita K. Occipital- axis posterior wiring and fusion for atlantoaxial dislocation associated wothoccipitalization of Atlas. J Neurosurg. 1993;79:142–4.
27. Hensinger R. Osseous anomalies of the craniovertebral junction. Spine. 1986;11:323–33.
28. Jayanthi V, Kulkarni R, Kulkarni R. Atlanto - Occipital Fusion - Report of Two Cases. J Anat Soc India. 2003;52(1):71–3.
29. Monalisa P, Bhatnagar R. Atlantooccipital fusion: A case report. Med J DY Patil Univ. 2015;8:636–8.
30. Brues A. Identification of Skeletal Remains. J Crim Law Criminol. 1955;48(5):549–61.
31. Kumar A, Harish D, Singh A, Kulbhushan K. Unknown Dead Bodies: Problems and Solutions. J Indian Acad Forensic Med. 2014;36(1):76–80.
32. Sharma B, Harish D, Singh V. Dead can tell tales- a report of two exhumed bodies. J Punjab Acad Forensic Med. 2004;4:29–32.
33. Sharma M, Baidwan S, Jindal A, Gorea R. 33. Sharma M, Baidwan S, Jindal AK, Gorea RK. A study of Vertebral Synostosis and its clinical significance. J Punjab Acad Forensic Med Toxicol. 2013;13(1):20–4.

Stray bullet as a cardiac embolism

Dr. Hussein Chahrour, M.D. The Lebanese Ministry of Justice, Sami Solh Avenue, Parc sector, Beirut, Lebanon.
The Lebanese Society of Forensic Medicine, Airport Street, Beirut, Lebanon.

Citation: Chahrour H. Educate: Stray bullet as a cardiac embolism. *Int J Eth Trauma Victimology 2016*; 2(2):38-41. doi: 10.18099/ijetv.v2i02.6861

Article history

Received: Oct 6, 2016
Received in revised form: Nov 11, 2016
Accepted: Nov 28, 2016
Available online: Dec 28, 2016

Corresponding author

Dr. Hussein Chahrour, The Lebanese Ministry of Justice, Sami Solh Avenue, Parc sector, Beirut, Lebanon.
The Lebanese Society of Forensic Medicine, Airport Street, Beirut, Lebanon

Phone:+961-3-732430
Email: husseinchahrour.forensics@gmail.com

Abstract

Bullet embolism is a relatively uncommon complication of gunshot injuries. Migration of bullets through bodily vessels presents unique clinical challenges and can lead to infection, thrombosis, ischemia, hemorrhage, and death. Potential lack of early symptoms leads to delayed or missed diagnosis and often-inadequate early management can potentially result in the loss of extremities or life. In this paper is presented an unusual case in which a stray bullet to the posterior aspect of the left side of the chest penetrated the thoracic cavity and traveled to the left femoral artery through the left ventricle, embolizing the vessel. The bullet was surgically removed from the left common femoral artery.

Keywords: Embolism, stray bullet

© IJETV. All rights reserved

Introduction

Celebratory gunfire (also called aerial firing or happy fire) is the shooting of a firearm into the air in celebration. Although practiced illegally, celebratory gunfire is culturally accepted in Lebanon and is fairly common, especially on New Year's Eve, during wedding ceremonies, national occasions, political events, and even at funerals.

Aerial firing may result in random death and injury. People can be injured, sometimes fatally when bullets discharged into the air fall back down to the ground. In Beirut, from March 30, 2016, to May 25, 2016, five people were the victims of stray bullets. One of the victims, a seven-year-old girl, received head injury and instantly passed away. The other four victims received a serious chest and abdominal injuries and were treated successfully. One of them, the subject of this report, received an aerial shot to the posterior aspect of the left chest, entering the left ventricle and finally found lodged in the left common femoral artery.

Bullet embolism after aerial firing is a rare yet fascinating phenomenon. The over growing incidence of aerial firing in civilian urban settings has increased the possibility of encountering strange and undefined types of bullet injuries. This is particularly applicable because bullets fired into the air usually fall back with terminal velocities much lower than their muzzle velocity,which is when they leave the barrel of a firearm. When such bullets enter the body, most of their kinetic energy has been dissipated, so when they enter a bodily vessel with no kinetic energy, the flow of the bloodstream sweeps the bullet away along with the blood current to a different site, usually a branch of the vessel where it first entered, resulting in embolism. Most of these emboli are asymptomatic and cannot be accurately evaluated at the emergency ward. If the entry wound of a bullet does not match with clinical findings, remote imaging is often required, provided the patient remains hemodynamically stable (1).

Case report

An active healthy 24-year-old male was walking down the street and bent to pick up his keychain after accidently dropping them. Suddenly he felt a severe sting under his left scapula. The patient asked his friend to examine his shoulder and was told that “it looks like a bullet injury, there is some blood”. The patient was then admitted to a nearby hospital

and upon arrival, he was dyspneic, tachypneic, with PR=140/min, BP=120/70 mmHg, RR=28, saturation 99% on a face mask, and a temperature of 37.2°C. The patient suffered from chest pain and was conscious, alert, and oriented to person, place, and time.

The primary survey revealed clear airways, with bilateral decreased breathing sounds (left side). All peripheral pulses were palpable and symmetrical except the left dorsalispedis, which was absent. Brief neurological examination showed GCS 15 moving all his extremities with gross intact sensory and motor functions. A large-bore intravenous access line was established on Ringer's lactate. Examination of the torso revealed a solitary wound in the left upper back, under the left scapula. There was no obvious active bleeding; the wound was circular with an abrasion zone and an 8 mm diameter. Upon secondary survey, no other wounds were detected. A chest X-ray was ordered as an adjunct to the primary work up, revealing bilateral pleural effusion L>R, with minimal left side pneumothorax. There was an absence of any foreign bodies. A total body scan was ordered and revealed:

- Left superior thoracic wall emphysema
- Minimal pneumothorax in left thoracic apex
- Mild bilateral pleural effusion (L > R)
- Minimal pericardial effusion
- Condensation at the base of the left lung with a linear tract from posterior of the left chest to posterior aspect of the left ventricle
- Small air bubble in the pericardium (cardiac wound)
- A bullet is detected in the left inguinal region adjacent to the left common femoral artery

At the theater, a chest tube was inserted in the left chest cavity. By this time the patient's lower left extremity became increasingly pale. Knowing that a bullet is lying in the left inguinal region, the surgeon immediately opened up the area to palpate the bullet inside the left common femoral artery and successfully removed it.

Next day the victim was transferred to Beirut Cardiac Institute for the possibility of an open heart surgery, upon arrival, a chest CT scan was performed, a cardiac echography as will as a transesophageal echography was performed. The CT scan did not show any changes from the initial one and the echographies were both negative. The clinical evaluation found the patient in stable condition. A decision was made to observe him in the CCU and to treat him conservatively.

The patient's condition improved and he was discharged home, with normal breathing sounds, and normal heart sounds with no murmurs (BP=120/80 mmHg, PR=100/min). A chest X-ray on May 14, 2016, revealed clear lung fields, normal heart size and shape, and free pleural space.

Discussion

Historically, Thomas Davis reported the first bullet embolism in 1834. Between 1834 and 1996 only 160 cases of bullet embolism were reported (1). Embolization of a bullet is very uncommon, with an incidence rate of about 0.3%. Out of the 7,500 firearm injuries reported in the Vietnam war, only 22 cases were complicated by foreign emboli, with 19 arterial cases as reported by Rich and colleagues (2). Slobodan and colleagues mentioned that more than 70% of cases of missiles penetrate into the arterial circulation through either the thoracic or abdominal aorta or even through the heart (3). Bullet emboli are usually associated with a small caliber, low-velocity missiles. Patel et al. reported an embolus incidence of 55% with a 0.22-caliber handgun compared to only 27% with a shotgun (4). The gun and ammunition used in the trauma play an important role in the diagnosis because bullet emboli are more common with smaller, blunt nose, and short length or low-velocity bullets. For a projectile to become an embolus, two major prerequisites need to be satisfied. First, the bullet should have little kinetic energy remaining at the precise instant it enters the blood vessel. Second, the diameter of the bullet must be less than the diameter of the blood vessel it penetrates. This explains why the incidence of bullet embolism is so low in war scenarios.

In our present case, a stray bullet hit the victim under his left scapula, and the bullet was a 7.62 caliber, which can easily penetrate the skin.

Unfortunately, it did not hit the scapular bone or a rib or other solid tissues that could have halted its progression into the chest, causing pleural effusion. As was noticed, the bullet did not tumble, and instead went directly inside the chest nose ahead

and managed to cross forward to enter the left ventricle causing a little pericardial effusion.

Fig. 1: (a) The bullet after removal (cartridge 7.62x39mm).(b)the Inguinal surgical site where the bullet was removed, (c)External location of the entry wound. (d) Close view of the entry wound.

Fig. 2: Chest X-ray showing left chest tube and left pleural effusion.

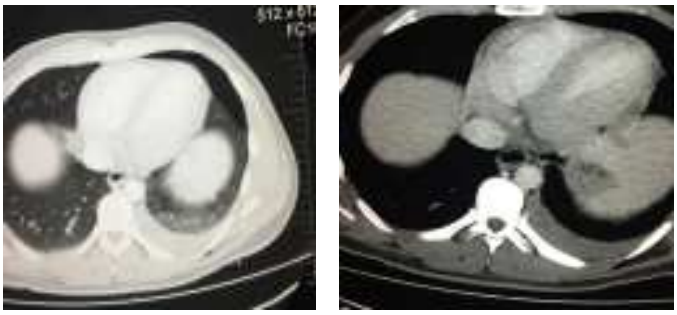

Fig. 3: CT scan of the chest showing left pleural effusion and left pneumothorax (left), and mild pneumopericardium (right).

Fig.4: CT Scan of the chest, abdomen, and pelvis showing gunshot tract (left, red arrow) and a metallic bullet in the left inguinal region (right, red arrow).

This did not increase in the following days because the inlet into the cardiac muscles of a young healthy adult had sealed. In the left ventricle, a foreign inert body was carried by the blood stream through the aortic valve to the aorta and was finally lodged in the left common femoral artery, causing the left lower extremity to become pale and painful. In 80% of cases, such emboli are symptomatic, causing claudication, and peripheral ischemia mainly in the lower extremity(5).

Bullet embolism should be suspected if the victim sustains a firearm injury, with no exit wound, and no missile is found in the area of direct trauma. In this case, a whole body X-ray should be performed, as the bullet may have traveled with the blood flow. MRI should be avoided in case the projectile has a ferrous component (6). Instead, a total body scan was used in the presented case in addition to cardiac and trans-esophageal echographies.

Conclusion

This case demonstrates how a bullet may migrate far from its entry wound. It is not always easy to predict the outcome of a stray bullet injury. The true path of a bullet or a pellet cannot be determined solely by considering the inlet wound site. Although the majority of stray bullet injuries to the body can be found lodged in the organ they were targeted at, they are rarely lethal. A bullet penetrating the chest is by itself a serious injury, however not finding the bullet anywhere around the chest area, complicates the case and presents the challenges brought about by arterial embolism. In this case, the single inlet with no exit wound and the fact that no bullet was identified around the target organ, were clear signs of bullet embolism. A thorough and meticulous search should be employed to save an organ or a life.

Acknowledgements

Special thanks to Mr. Ali Chahrour for help with manuscript editing.

References

1. Biswas S, Cadot H, Abrol S. Gunshot wound of the thoracic aorta with right popliteal artery embolization: a case report of bullet embolism with review of relevant literature. Case Rep Emerg Med 198617. 2013;2013:198617.
2. Rich N, Collins G, Jr., Andersen C, McDonald P, Kozloff L, Ricotta J. Missile emboli. J Trauma. 1978;18:236–9.
3. Slobodan S, Slobodan N, Djordje A. Popliteal artery bullet embolism in a case of homicide: a case report and review of the tangible literature. Forensic Sci Int. 2004;139:27–33.
4. Patel K, Cortes L, Semel L, Sharma P, Clauss R. Bullet embolism. J Cardiovasc Surg Torino. 1989;30:584–90.
5. Michelassi F, Pietrabissa A, Ferrari M, Mosca F, Vargish T, Moosa H. Bullet emboli to the systemic and venous circulation. Surgery. 1990;107:239–45.
6. Sandler G, Merrett N, Buchan C, Biankin C. Abdominal shotgun wound with pellet embolization leading to bilateral lower limb amputation: case report and review of the literature of missile emboli over the past 10 years. J Trauma. 2009;67:202–8.

Letters to Editor

Dear Sir

Let me congratulate you on bringing out the first issue of Volume 2 of International Journal of Ethics, Trauma & Victimology. This sincere effort by you for such an academic activity is going to help society as well as an academician in updating their knowledge in ongoing developments in various scenarios.

I have gone through contents of paper titled 'Recent legal aspects of medical negligence' contributed by Bala R and Chanana A. They have rightly pointed towards various legal aids and judgments given by Highest Court of India, Supreme Court, in various alleged negligence cases. These judgments and certain circulars by Senior Police officials are helpful for a Practitioners but here I want to emphasize that usually, theactual story is different (1). Usually, when we read about any news related to allege case of negligence by any doctor, either the police have arrested that doctor immediately or have issued an arrest warrant against that doctor and that too without taking opinion from any other doctor/ board of doctors. This is done even when there are clear instructions by the Honorable Supreme Court. Whenever asked for such an action, the police official always give the excuse that as mob supporting the victim or their family pressurized them by either blocking traffic or gheroing of the police station, even vandalizing the hospital (2),(3), so to maintain law & order, they had to register a case against the doctor. They may be right on their part but sometimes this laxity of police further encourages other people to harass medical fraternity and sometimes even exploit them over this fear. This is not only limited to India but almost reported many other parts of the world (4).

I hope some changes in rules (criminal procedure adopted in investigating such cases) or exemplary actions against such harassment and exploitation will surely going to allay the fear and stress of which Medical Practitioners are treating their patient presently.

Reference:

1. Ahluwalia K. Punjab prohibits arrest of doctors [Internet]. The times of India city. 2004 [cited 2016 Dec 15]. Available from: http://timesofindia.indiatimes.com/city/chandigarh/Punjab-prohibits-arrest-of-doctors/articleshow/596421.cms
2. Yengkhom S. Hospital vandalised over alleged medical negligence [Internet]. 2016 [cited 2016 Dec 15]. Available from: http://timesofindia.indiatimes.com/city/kolkata/Hospital-vandalised-over-alleged-medical-negligence/articleshow/54670708.cms
3. TNN. Hospital vandalized over patient's death [Internet]. 2016 [cited 2016 Dec 16]. Available from: http://timesofindia.indiatimes.com/city/bareilly/Hospital-vandalized-over-patients-death/articleshow/55017954.cms
4. Tribune Correspondent. Alleged medical negligence: Relatives of deceased man vandalise Services Hospital emergency ward [Internet]. 2012 [cited 2016 Dec 16]. Available from: http://tribune.com.pk/story/424909/alleged-medical-negligence-relatives-of-deceased-man-vandalise-services-hospital-emergency-ward/

Dr Amandeep Singh
Associate Professor
Dept. of Forensic Medicine & Toxicology
Government Medical College & Hospital
Chandigarh, INDIA

Dental Ethics

"Man ultimately decides for himself, and in the end, education must be education toward the ability to decide." Viktor Frankl

The **Principles of Ethics** are the aspirational goals of the profession. They provide guidance and offer justification for the *Code of Professional Conduct* and the *Advisory Opinions*.

"Dental Ethics deals with moral contact, duty, and judgment. It's concerned with standards for determining wither actions are right or wrong. These are voluntary controls, not laws, and serve as a method of self-polishing within a profession." The terminal objective is the dentist will choose to apply the principles of professional ethics to his or her practice of dentistry.

Hippocratic Oath"I will use treatment to <u>help</u> the sick according to my ability and judgment, but I will never use it to injure or wrong them."

Enabling Objectives are the student dentist will be able to: define the principle of beneficence and explain the dentist's role in applying the principle in caring for patients. To relate nonmaleficence to beneficence, to describe the principle of respect for autonomy, to describe the three ingredients of a valid or informed consent, to explain the relationship of gaining a valid consent from patients to the ethical principles of beneficence and respect for autonomy, to explain "paternalism," to justify a dentist's ethical obligation to "lifelong learning," to apply the three aspects of Rawl's principle of justice to the practice of dentistry, to explain why there exists a societal expectation for self-regulation in the learned' professions generally, and dentistry specifically.

American Dental Assistants Association Principals of Ethics states that this code of ethics functions as a standard of ethics for all practicing dental assistants. Each individual involved in the practice of dentistry assumes the obligation to maintain and enrich the profession. Each member may choose to meet this obligation according to the dictate of personal conscience based on the needs of the human beings the profession of dentistry is committed to serving. The spirit of the Golden Rule is the basic guiding principle of this concept. The member must strive to maintain confidentiality and to exhibit respect for the dentist. The member shall refrain from performing any professional service that is prohibited by state law and has obligation to prove competence prior to providing services to any patient. The member shall constantly strive to upgrade and expand technical skills for the benefit of the employer and the consumer public. The member should additionally seek to sustain and improve the local organization, state association, and the American Dental Assistants Association by active participation and personal

Further, it is also very important to understand what is unethical in dental practice, by a dentist, dental assistants, and dental students. Practice by unregistered persons employed by the dentists; represent itself in a manner that is false or misleading and representing their fees in deceptive manner; issuing any certificate signed by the dentist which is untrue, misleading or improper; non-referral, in case treatment beyond the dentist skill; performing unnecessary services for purpose of monetary gain; emerging consultation during temporary absence of patient's dentist, and patient is not sent back; dentist advertising whether directly or indirectly, for purposes of obtaining patients.

Parul Khare Sinha
MDS Oral Pathology
MSc Masters Forensic Odontology
Assistant professor
Department of Oral Pathology
College of Stomatology
Ninth peoples Hospital
Shanghai Jio Tong University School of Medicine
639, Zhi Zao Ju Road, Shanghai
China

Instructions to authors

Preparing a Manuscript for Submission to International Journal of Ethics, Trauma and Victimology

Unpublished original manuscript written in English should be sent to:

Dr. RK Gorea, Editor, International Journal of Ethics, Trauma & Victimology by email at editoretv@gmail.com

The Publication Particulars

The IJETV is the publication supported by SPIC, published since 2015.

The Contents of the Journal

The journal accepts a range of articles of interest, under several feature sections as follows:

- Original Papers: Includes conventional observational and experimental research.
- Commentary: Intended for Reviews, Case Reports, Preliminary Report and Scientific Correspondences.

Letter to the Editor

Designed to be an avenue for dialogue between the authors of the papers published in the journal and the readers restricted to the options expressing reviews, criticisms etc. It could also publish letters on behalf of the current affairs in the field of Ethics, Trauma & Victimology

Editorial

Intended as a platform, for the Editor-in-Chief and for others with a keen interest in Ethics, Trauma & Victimology that wished to comment on the current affairs.

Special Features

Book Review, Abstracts, Announcement etc, which appear frequently, but not necessarily in every issue related to Ethics, Trauma and Victimology.

News and Notes

Intended for providing information of members and activities of the Society and other such other organizations affiliated to the Society may appear frequently and not in every issue.

General Principles

The text of observational and experimental articles is usually (but not necessarily) divided into the following sections: Introduction, Methods, Results, and Discussion.

This so-called "IMRAD" structure is not an arbitrary publication format but rather a direct reflection of the process of scientific discovery. Long articles may need subheadings within some sections (especially Results and Discussion) to clarify their content. Other types of articles, such as case reports, reviews, and editorials, probably need to be formatted differently. Electronic formats have created opportunities for adding details or whole sections, layering information, cross-linking or extracting portions of articles, and the like only in the electronic version. Double spacing all portions of the manuscript— including the title page, abstract, text, acknowledgments, references, individual tables, and legends—and generous margins make it possible for editors and reviewers to edit the text line by line and add comments and queries directly on the paper copy. If manuscripts are submitted electronically, the files should be double-spaced to facilitate printing for reviewing and editing. Authors should number all of the pages of the manuscript consecutively, beginning with the title page, to facilitate the editorial process.

International Uniform Requirements

Please visit **http://www.icmje.org/** for detailed instructions for manuscript submission.

Review process

All the articles received are peer reviewed. It is double blind review process. Articles are only published after the completion of the review process.

Society for Prevention of Injuries and Corporal Punishment (SPIC)

(HO: DAV School, Patiala, India)

GOVERNING COUNCIL (2013 - 2016)		
Chief Patron Mr. SR Prabhakar, India **Director Coordinator** Mr. Abhinav Gorea, Australia	**President** Dr. RK Gorea, Kingdom of Saudi Arabia **Vice Presidents** Dr. Clifford Perera, Sri Lanka Dr. SS Sandhu, India **General Secretary** Dr. Rajiv Joshi, India **Joint Secretary** Mr. Kiranjit Kaur Bawa, India **Treasurer** Dr. Pardeep Singh, India	**Press Secretary** Mr. BijendraShastri, India **Web Administrator** Dr. Imran Sabri, Kingdom of Saudi Arabia **Executive Members** Dr. BL Bhardwaj, India Mr. Vijay Kumar Goyal, India Dr.ManeelGrover,India Dr.Kuldeep Singh, India Mr. SK Sharma , India Mrs. Paramjeet K Bawa, India

FOUNDER TEAM		
President Dr. RK Gorea, Kingdom of Saudi Arabia	**Director Coordinator** Mr. Abhinav Gorea, Australia	**Chief Patron** Mr. SR Prabhakar, India
Vice Presidents Dr. Clifford Perera, Sri Lanka Dr.Kusum Mahajan, India	**Secretary** Dr.Kiranjit Kaur Bawa, India	**Treasurer** Dr. KK Aggarwal

LIFE MEMBERS			
LM 1	Dr. Vijay Pal Khanganwal, India	LM 20	Dr. S. Manju Nath, India
LM 2	Dr. Harish Dasari, India	LM 21	Dr. Haneil Dsouza
LM 3	Dr. Krishan DuttChawali, India	LM 22	Dr. Ashwini Kumar, India
LM 4	Dr. Yogender S. Bansal, India	LM 23	Dr. Shankar M. Bakhannavar, India
LM 5	Dr. Akas Deep Aggarwal, India	LM 24	Dr. Dalbir Singh, India
LM 6	Dr. Pankaj Gupta, India	LM 25	Mr. Gaiwale Sanjay D. , India
LM 7	Dr. Pardeep Singh, India	LM 26	Dr. Jambure Mahesh Panditrao, India
LM 8	Dr.SarveshTandon, India	LM 27	Dr. PrashanthaBhagavath, India
LM 9	Dr. CB Jani, India	LM 28	Dr. Vinay Kumar M.S. , India
LM 10	Dr. M. Ravinder Reddy, India	LM 29	Dr. N VeerandraKoushik, India
LM 11	Dr. Amandeep Singh, India	LM 30	Dr. S.K. Roychaudhary, India
LM 12	Dr. Chandra Prakash, India	LM 31	Dr. B.D. Gupta, India
LM 13	Dr. Imran Sabri, India	LM 32	Dr. Prabh Sharan Singh, India
LM 14	Dr. BM Naga Mohan Rao, India	LM 33	Dr. A. Shankar Rao, India
LM 15	Dr. Ritu, India	LM 34	Dr. Pradeep Kumar Mishra, India
LM 16	Dr BV Subrahmanyom, India	LM 35	Dr. Parmod K. Goyal, , India
LM 17	Dr. Shri Kant Asawa, India	LM 36	Dr. J.N. Som, India
LM 18	Dr. S. Shavvkath Ali, India	LM 37	Dr. Arsalaan F. Rashid
LM 19	Dr. M.F. Bansal, India	LM 38	Dr. Clifford Perera, Sri Lanka
LM 39	Dr. Ashok Sharma, India	LM 89	Mr. Hartish Sharma, India
LM 40	Dr. PS Thakur, India	LM 90	S. Sharanveer Singh Kahlon, India
LM 41	Dr. Arshad Anjum, India	LM 91	S. Kunwar S Deep Singh, India

LM 42	Dr. Mukesh Yadav, India	LM 92	Mr. Mohit Kason, India
LM 43	Mr. AzfarMateen, India	LM 93	Mr. RishabWalia, India
LM 44	Dr. Mohammad Shuaib, India	LM 94	Mr. Lakesh Kumar, India
LM 45	Mr. MD ShadafRaheel, India	LM 95	S. Ripu Daman Singh, India
LM 46	Dr. Mohd. Kaleem Khan, India	LM 96	Mr. Harnoor Bhardwaj, India
LM 47	Dr. Lalit Kumar, India	LM 97	Mr. Girish Behag
LM 48	Dr. Mahendra Kumar Pant, India	LM 98	Ms. Luvleen Gorea, India
LM 49	Dr. Akhilesh Agarwal, India	LM 99	Mrs. Anita kataria, India
LM 50	Dr. HrishikeshBaruah, India	LM 100	Mr. Yash Paul Sharma, India
LM 51	Mr. Abhinav Gorea, Australia	LM 101	Mr. AnirudhaAgnihotry, USA
LM 52	Dr. SS Sandhu, India	LM 102	Dr. PremParkash Khosla, India
LM 53	Dr. Anil Garg, , India	LM 103	Mrs. Sudha Sharma, India
LM 54	Dr. Anurag Arora, Australia	LM 104	Mr. Aditya
LM 55	Sh. BijenderShastri, India	LM 105	Dr. Sukhraj Singh Sahota, India
LM 56	Ms. Kirandeep Dhaliwal, India	LM 106	Mr. Atul Suri
LM 57	Sh.Samir Kumar Patel, India	LM 107	Mr. S K Singhal
LM 58	Dr. Vikas Joshi, India	LM 108	Sr. Ashutosh Garg
LM 59	S. JaswantBrar, Canada	LM 109	Dr. RifatFazli
LM 60	Mr. SR Prabhakar, India	LM 110	Dr. Norazin BT Kama Nok, Malaysia
LM 61	Ms. Kirandeep Kaur Bawa, India	LM 111	Ms. Aimyleen V Gabriel
LM 62	Mr. Sandeep Sharma, India	LM 112	Dr. Rajiv Seth, India
LM 63	Dr. Kusum Sharma, India	LM 113	Ms. Patria Weston Lee, USA
LM 64	Dr. R K Gorea (Patron member)	LM 114	S. Sukhdev Singh
LM 65	Dr.JP Singh, India	LM 115	Dr. Satish Gupte
LM 66	Dr. Harjinder Singh (Patron member)	LM 116	Dr. Harkesh Kumar
LM 67	Dr. Sanjay Singla	LM 117	Dr. Bindu Aggarwal
LM 68	Dr. Kusum Mahajan, India	LM 118	Ms. Ravneet Sandhu
LM 69	Dr. AartiSareen, India	LM 119	Mr. Shahbaz Zafar
LM 70	Mr. Chetan Gupta, India	LM 120	Dr. Gagandeep Kaur Ghai
LM 71	Dr. Gurbachan Singh, India	LM 121	Dr.Jasbeer Singh Sandhu
LM 72	Dr. Manish Sharma, India	LM 122	Mr. Nipun Gupta
LM 73	Dr. Rishi Nabh, India	LM 123	Dr. Meet Kamal
LM 74	Dr. Mandeep Singh, USA	LM 124	Dr. ParampreetPannu
LM 75	Dr. OP Jasuja, India	LM 125	Dr. Ramesh R Fry
LM 76	Dr. Vinod Kapoor, India	LM 126	Dr. Deepak K Gupta
LM 77	Dr. K K Aggarwal, India	LM 127	Ms Navpreet Kaur
LM 78	Dr. B L Bhardwaj	LM 128	Dr. S K Saxena
LM 79	Mr. Prem Goyal, India	LM 129	Dr. PPS Cooner
LM 80	Dr. SK Dattarwal, India	LM 130	Dr. Jagmohan Singh
LM 81	Mr. RupayanJasuja, , India	LM 131	Dr. M Neeti
LM 82	Mr. MannatSirahi, , India	LM 132	Dr. Rajiv Sharma
LM 83	S. HarshKaranveer Singh, India	LM 133	Mr. Vijay Kumar Goyal
LM 84	Ms. Parneet Kaur, India	LM 134	Dr. F Asicioglu, Turkey
LM 85	Mr. CharishaGoel, India	LM 135	Ms. AnuradhaSangal, India
LM 86	Mr. Nitika Bansal, India	LM 136	Ms. Divya Dubey, India
LM 87	Ms. Inderjit Kaur, India	LM 135	Ms. Kusum Jain, India
LM 88	Mr. Rajat Khanna, India	LM 136	Girish Behal, India
LM 137	Dr.ManeelGover, India	LM 144	Dr. Rajiv Joshi, India
LM 138	Dr.Parul Sinha, Belgium	LM 145	Dr. Abhishek Varshney, India
LM 139	S. Kulbir Singh Brar, India	LM 146	Dr. Amjad Bhatt, India

LM 140	Ms.Kiranjeet Kaur Dhaliwal, India	LM 147	Dr. Ranvir Singh, India
LM 141	Ms. Paramjeet Kaur Bawa, india	LM 148	Dr. Farida Tabassum, India
LM 142	Dr.Parul Sinha, China	LM 149	Dr. Kirti Vardhan Singh, India
LM 143	Mr Vijay Kumar, India	LM 150	

Middle East Wing of SPIC

GOVERNING COUNCIL (2013 - 2016)		
Chief Patron Mr. SR Prabhakar, India **Director Coordinator** Mr. Abhinav Gorea, Australia **President** Dr. RK Gorea, Kingdom of Saudi Arabia **Web Administrator** Dr. Imran Sabri, Kingdom of Saudi Arabia	**Regional Coordinator** Dr. Gulam Mustafa, Kingdom of Saudi Arabia **Regional Co-coordinator** Dr.Shashi Shekhar, Kingdom of Saudi Arabia **General Secretary** Dr.SubhashMashal, Kingdom of Saudi Arabia **Joint Secretary** Dr.Shafqat Qamar, Pakistan	**Treasurer** Dr. Syed Shoaib Raza Rizvi, Pakistan **Executive Members** Dr. Mohammed Sarosh Khan, Kingdom of Saudi Arabia

Middle East Wing of SPIC –Life Members			
S. No.	Name	S. No.	Name
MEW LM 1	Dr. Mohammed Sarosh Khan, Kingdom of Saudi Arabia	MEW LM 7	Dr. Shashi Shekhar, Kingdom of Saudi Arabia
MEW LM 2	Dr. Syed Shoaib Raza Rizvi, Pakistan	MEW LM 8	Dr. SubhashMashal, Kingdom of Saudi Arabia
MEW LM 3	Dr. Shafqat Qamer, Pakistan	MEW LM 9	Dr. Deepak Pathania, Kingdom of Saudi Arabia
MEW LM 4	Dr. Gulam Mustafa, Kingdom of Saudi Arabia	MEW LM 10	Dr. George Sam, KSA
MEW LM 5	Dr. AbdulwahabAbuderman, Kingdom of Saudi Arabia	MEW LM 11	Dr. Gulfam Ahmed, Pakistan
MEW LM 6	Dr. Sameer Hamed Al Ghamdi, Kingdom of Saudi Arabia		

Society for Prevention of Injuries & Corporal Punishment [SPIC]

HO: DAV School, Patiala, 147001 India

http://www.spic.org

Application for Membership

To

The General Secretary
Society for Prevention of Injuries and Corporal Punishment

Dear Madam,

I wish to become a Life Member of SPIC. I am furnishing the required particulars below with a request to enroll me in the Society. The fee of Rs. 1000 In India/ 200 Riyals in KSA/US $ 100 in any other country for Life Membership is enclosed as a Demand Draft with No_____ Of _____Bank, in the name of SPIC, payable at the Patiala city or the office of General Secretary of the Society along with my two passport size photographs.
I have gone / will go through the rules and regulations of the academy and I agree to abide by the same.

PARTICULARS

1. Full Name (in block letters)_____
2. Father's / Husband's name _____
3. Date of Birth _____
4. Qualification (with name of university & date of passing) _____

   _____
5. Official Designation _____
6. Place of Posting _____
7. Permanent Address_____

   _____
8. Address for Correspondence (subsequent change of address to be intimated) _____

   _____
9. Phone No._____Email _____

Place
Date

Yours Sincerely

(Signature)

FOR USE OF SPIC
Membership Accepted with Life membership No. / SPIC / / Dated

President **Treasurer** **Regional Coordinator/Director Coordinator**

CME being held at Prince Sattam bin Abdulaziz University, Al Kharj, Kingdom of Saudi Arabia on Oct 29 to Oct 30, 2016

Global scenario of corporal punishment in schools being discussed at the CME

With best compliments from

Middle East Wing of

SPIC

Society for Prevention of Injuries and Corporal Punishment

at the release of

2nd issue of Volume 2, 2016

of

International Journal of Ethics, Trauma and Victimology